

Aortic stenosis is narrowing of the aortic valve opening, a common and a slowly progressive disease in the elderly population but with the onset of symptoms, one in two die within a couple of years. In this condition, the aortic valve within the heart undergoes degeneration (wear & tear) due to aging. It is common in old age, as calcium or scarring damages the valve and restricts the amount of blood flowing through the valve, but can occur at a younger age if the valve is abnormal by birth.

Due to aortic stenosis, the heart needs to work harder to pump blood and this eventually weakens heart muscle. Left untreated, aortic valve stenosis can lead to life-threatening heart problems. In spite of this fact, many patients especially the older age group, cannot have conventional valve replacement or repair surgery owing to the prohibitively high surgical risk.

Patients having evidence of symptomatic and severe calcific valvular aortic stenosis, but also having high surgical risks when assessed by EURO and STS scores, have a new and minimally invasive option –the TAVR (Transcatheter aortic valve replacement).

### TAVR VS OHS

TAVR is the new alternative for select patients for whom traditional open chest surgery has intermediate or high risk. This minimally invasive procedure repairs the narrowed aortic valve without a major surgery. A catheter is placed in the femoral artery (in the groin) similar to

angioplasty, and guided into the chambers of the heart. A compressed tissue heart valve is placed on the balloon catheter and is positioned directly inside the diseased aortic valve. A team of interventional cardiologists and imaging specialists, heart surgeons and cardiac anesthesiologists work together, utilizing fluoroscopy and echocardiography to guide the valve to the site of the patient's diseased heart valve.

A typical patient will get the diagnosis confirmed by his symptoms and echocardiography and his operative risk will be assessed objectively by the EURO score II. Accordingly if TAVR is decided, CT coronary angiogram and an aortogram up to the femorals will be taken to assess the anatomical feasibility of the vessels. If suitable, the patient will be admitted to hospital a day before the planned procedure and will usually undergo the procedure under local anaesthesia. Typically the patient can walk on the second day and can go home by day five.

TAVR has indeed been a boon to many elderly patients even over the age of 75 and has given them a second lease of life and am sharing our experience.

### PATIENT 1

#### Presentation & Evaluation:


Mr P was a 73 years old diabetic, hypertensive and CAD patient who had undergone PCI in 2006 and CABG in 2011. He was a known case of CKD and severe COPD requiring BiPAP at home.

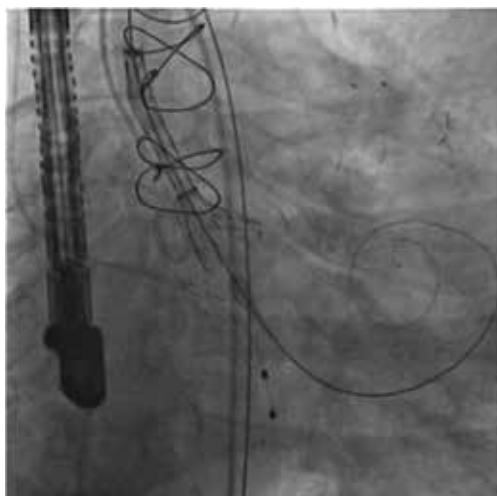
From January 2014 to October 2015, he had spent more than 5 months as inpatient that included three months of Intensive care. In October 2015 he was consulted for inability to wean from ventilation in spite of good care for COPD.

Echocardiogram showed critical aortic stenosis and there was severe PAH with preserved bi-ventricular function. CT surgeons refused aortic valve surgery in view of his high risk, co-morbid conditions and previous thoracotomy. His STS score predicted mortality and morbidity for surgical AVR was 23% and 50% respectively signifying very high risk for open surgery. After confirming his patent bypass grafts, CT assessment revealed suitability for core valve implantation.

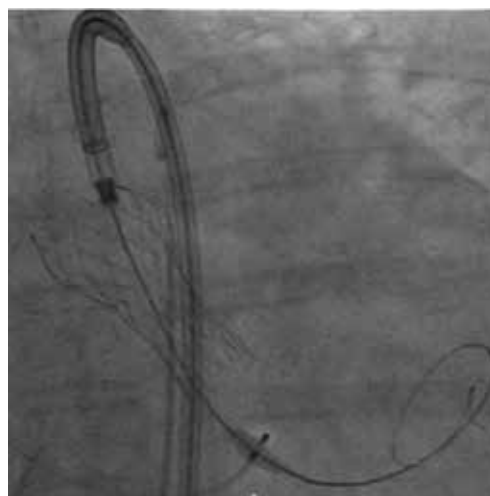
#### Procedure

The procedure was performed under short GA through the right femoral artery the native calcified valve was predilated before implanting a 26mm Medtronic core valve. The procedure was truly percutaneous (no cut

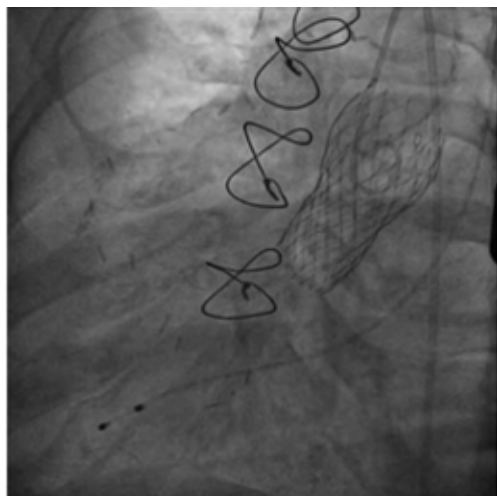




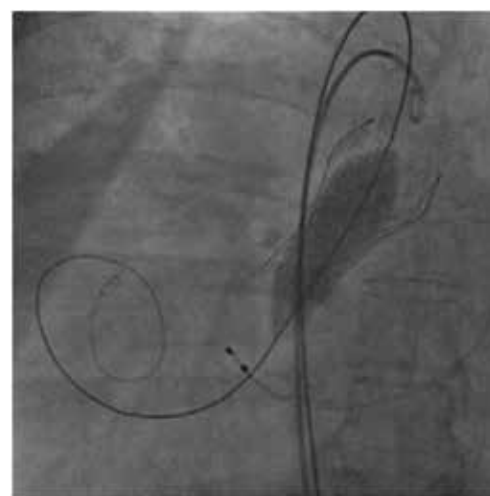
**Fig. 1 : Core Valve being deployed under TEE guidance**



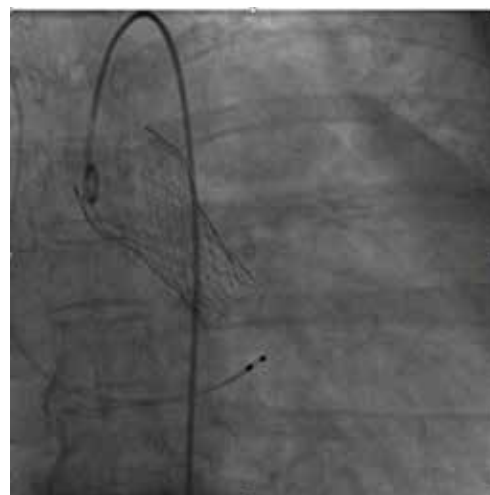
**Fig. 3 : Core Valve after Complete deployment**



**Fig. 2 : Core Valve after Complete deployment)**



**Fig. 4 : As there was a paravalvular leak, its being post dilated**



**Fig. 5 : Final result post dilation**

down required) and femoral arterial access site was pre-closed using specialized vascular closure device called the Proglide. There was immediate improvement in the hemodynamics (gradient reduced to normal and pulmonary arterial pressures significantly reduced) and echocardiogram showed normally functioning core valve with no para-valvular leak. Complete hemostasis was achieved in the lab and the whole procedure lasted for an hour and half. The patient was extubated post procedure in the ICU, and was discharged on day 5 (Figures 1 & 2).

#### **Follow up**

PAH which was attributed to COPD, also improved significantly to 44 mm of Hg from the initial 82 mm of Hg. This patient symptom improved significantly that he transformed from a state of depressed man requiring recurrent ICU admissions to a cheerful ambulant gentle man riding bi cycle.

#### **PATIENT 2**

##### **Presentation & Evaluation**

Mrs P was a 55 years old, diabetic, obese, post-menopausal lady, who presented with progressive dyspnoea on exertion over the last few years progressed to class IV in the last few months. She was diagnosed to have severe

aortic stenosis. Her house was a small nursing home with reclining short beds, a BiPAP machine, oxygen cylinders, walkers and special nurse assistance for day to activities. Her past history included diabetic foot, lower limb fractures, Infective endocarditis of a bi-cuspid aortic valve and obstructive sleep apnea. Her logistic Euro score was 16 with a predicated mortality and morbidity of 16% and

76 38% respectively for surgical AVR. Her CT scan revealed suitability for TAVR.

### Procedure

In spite of her multiple comorbidities, TAVR was performed under conscious sedation and was truly percutaneous without cut down. After predilatation during rapid ventricular pacing, a 29 mm Evolut-R second generation valve was deployed (smaller 14 F sized sheath and is retrievable and repositionable up to 80% deployment) (Figures 3, 4 & 5). Her hemodynamics instantly improved. Post procedure echo showed paravalvular leak which improved after post dilation. The access sites were pre-closed and the entire procedure was done in two hours. She was observed in CCU for 2 days, discharged on day 5. She had significant improvement in her symptoms and loss of weight.

### Follow up

Echo showed normally functioning EVOLUT R valve and normal LV function with no para-valvular leak. She had remarkable improvement in her symptoms and also lost 20 kgs in one month.

### PATIENT 3

#### Presentation & Evaluation:

Mr P, 64 years old diabetic, CKD with coronary artery disease and had undergone PCI in 2006, LV dysfunction and severe AS. He required ICU admission for LRI and worsening CKD. After stabilizing the patient, a low dose dobutamine stress echo showed presence of contractile reserve with mean AVG of 46 mm of Hg and surgical AVR considered to be high risk in view of LV dysfunction and a STS score predicted mortality and morbidity of 6% and 30% respectively. CT confirmed him suitable for TAVR and also his earlier stent was patent.

### Procedure

TAVR was done under local anesthesia with 29 mm Evolut R and was truly percutaneous through right femoral access. Post procedure there was no para-valvular leak and no gradient. He developed trifascicular block requiring permanent pacemaker implantation on day 3.

### Follow up

His symptoms greatly improved and he is fully ambulant, and able to perform his usual activities.

### PATIENT 4

#### Presentation & Evaluation:

Mr. S, 90 years old gentleman is a known diabetic, hypertensive, COPD, CKD and a CAD-S/P CABG patient. Since 2013 he was having recurrent heart failure admissions and was diagnosed with moderate aortic stenosis and severe LV dysfunction. The AS became severe and he progressed to class IV symptoms. In view of surgical risk surgical AVR was ruled out and he was considered for TAVR.

### Procedure

He underwent TAVI with a 29 mm Evolut R valve percutaneously (Figures 6 & 7). Intra procedure he had a transient asystole and was resuscitated successfully. He was mobilized the second day and discharged the third post procedure day. At one month follow up his renal functions improved to normal and his functional capacity improved to class II.

### Follow up

His symptoms greatly improved and he is fully ambulant, and able to perform all his usual activities.

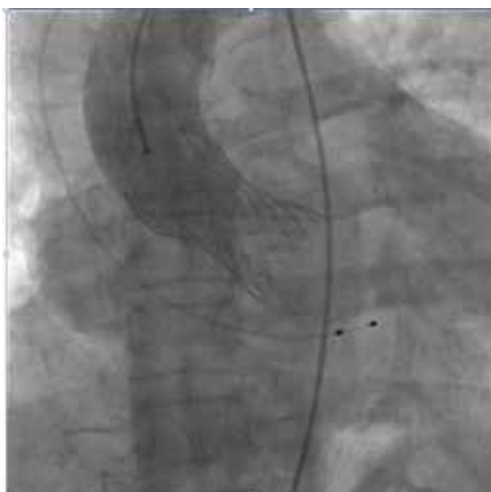### PATIENT 5

#### Presentation & Evaluation

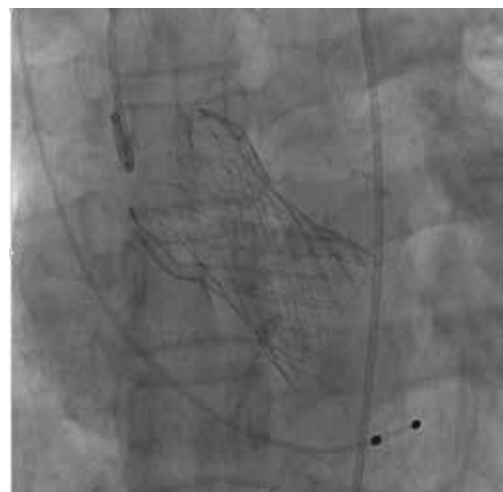Mr. Sk a 78 years old gentleman with class III NYHA DOE was diagnosed with bi-cuspid aortic valve with severe aortic stenosis and mild LV dysfunction. He was also diagnosed with interstitial lung disease and thrombocytopenia. In view of his moderate risk for surgical AVR he was offered the options of both TAVR and SAVR but patient and attendants opted for TAVI.

### Procedure

Accordingly he underwent the procedure under LA using a 29 mm Medtronic Evolut R valve completely percutaneously. Post procedure he was mobilized the



**Fig. 6 : Aortogram after valve implantation**



**Fig. 7 : Evolut R valve – post deployment**

second day and discharged on the third day and clinically he is doing very well.

### Follow up

He has recovered and feels well. According to him “This is my first hospitalization in my life and was very scared before and realized it is a simple procedure and now I am able to walk more without any symptoms”

### CONCLUSION

TAVR as its name goes is aortic valve implantation done as percutaneous based catheter implantable valves as opposed to an open surgical implant. The major advantage of TAVR versus surgical AVR is the fact that owing to its minimum invasive nature it can be done in patients who are too surgically moribund to undergo open surgery. In comparison, TAVR is shown to have similar 30 day and 1 year mortality and similar 30 day stroke rate to open surgery.

“TAVR is the treatment of choice for high risk patients with severe AS. Even in intermediate risk in elderly patients over 75 years, its safety and efficacy have been established and can be considered after assessment by a heart team.”

### FAQS

#### What is TAVR ?

TAVR is transcatheter aortic valve replacement which today is the alternative for surgical aortic valve replacement (AVR).

#### How is it different from surgical AVR

TAVR as its name goes is aortic valve implantation done as percutaneous based catheter implantable valves as opposed to an open surgical implant.

Advantages of TAVR versus surgical AVR - The major advantage of TAVR is the fact that owing to its minimum invasive nature it can be done in patients who are too surgically moribund to undergo open surgery. In comparison TAVR is shown to have similar 30day and 1 year mortality and similar 30 day stroke rate.

#### What are the indications for TAVR?

Patients with severe symptomatic valvular aortic stenosis with an echo derived mean gradient >40mmhg

High surgical morbidity as assessed by Euroscore and STS scores.

#### What are the valve types?

There are two types of valves commonly used , the self expanding Medtronic Core/Evolut R Valve and the balloon expandable Edwards Sapien 3 valve.

#### How are the patients selected for the procedure ?

For selection of patients for the procedure a detailed clinical evaluation, routine lab values chest xray, trans thoracic echo, PFT, carotid ultrasound , coronary angiography and CT Angiography of the aortic valve, chest, abdomen and pelvis. The CT angio is done to assess the aorto iliac patency, calcification and tortuosity. This is of utmost importance because the presence of occlusive PAD, small vessels and excessive tortuosity would preclude a trans femoral approach.

#### What are the methods of implantation?

The commonest site of implant is through the femoral route. The other less frequently employed route is subclavian and direct aortic. The newer valves are advantageous because of its smaller delivery system (14-18F).

#### When to refer a patient for TAVR?

Patients having evidence of calcific severe valvular aortic stenosis who are symptomatic can be referred to TAVR if the surgical morbidity as assessed by EURO and STS score is high.

#### Are all aortic stenosis patients eligible for TAVR?

Patients having severe symptomatic, calcific valvular aortic stenosis who are surgically moribund and are deemed to be at very high surgical risk currently are the candidates eligible for TAVR. The promising results of TAVR have prompted to expand its purview to intermediate risk candidates as well.

#### How many TAVR procedures have been performed? What is the current status in India?

Since the initial TAVR in 2002, over 2,50,000 procedures have been performed worldwide. Few centres in India including ours have already performed TAVR and TAVR is expected to grow in India.