

# Tropical CNS infections : one must not forget

*Ashish Bhalla, Parampreet S Kharbanda*

## Introduction

Acute febrile encephalopathy is a common problem in adults attending the emergency in India. (1) The physician is faced with this challenge in the emergency of identification of the clinical syndrome, establishing the aetiology and its prompt treatment not only to ensure survival but also to prevent long-term sequel in these patients. One has to be very meticulous while approaching such a patient because of the diversity of causes and equally large number of mimicking conditions. In untreated cases, mortality is very high and the survivors are often left with disabling neurologic sequelae. (2) Many a times even a detailed diagnostic workup may not identify a specific organism. (3) Nevertheless a detailed examination and workup is warranted as many conditions, such as infections are eminently treatable. (4)

## Epidemiology

Most cases are seen in the hot and wet months between July and October. (1,5,6) This is the season where all the vector borne diseases are abundant as the weather is conducive for the growth and survival of mosquitoes, which are important vectors for transmission of infections like Herpes, Japanese encephalitis, malaria and dengue.(7) .

There is a male preponderance in most of the reported studies, however, implying that males are more prone to develop these infections. (1,5,8) These findings indicate that males by virtue of their outdoor work activities are more prone to come in contact with vectors and are likely to fall ill or suggest that males being earning members of the family, get to the hospital earlier. These facts have not been addressed in any study till date. Most of the patients are young within 2nd to 4th decade of their lives. (1,5,8) The literature is silent on the differences in outcomes between young healthy adults compared to the elderly with multiple co morbidities and low reserve. It seems plausible that the illness would be severe in elderly but there is no evidence to suggest so.

## Symptoms

Fever and altered mental status are the most common presenting symptoms seen in almost 100% of patients, respectively.(1,5,8) Headache is encountered in 95-100% (1,8). Seizures at presentation is not a frequently encountered symptom and is seen in around 25% of the patients. (1) Although classically described with parenchyma involvement (encephalitis), acute pyogenic meningitis may also result in seizures in around 30% of patients. (7) Presence of seizures indicates involvement of brain parenchyma however its absence does not rule it out. Therefore presence or absence of seizures can not be commensurate with the diagnosis of viral encephalitis. Clinical signs indicating meningeal involvement may be present in only 25% patients.(1) whenever it is present, it indicates additional component of meningeal inflammation.

In one of the studies, patients with primary neurotropic viruses had shorter duration of fever and headache as compared to non viral aetiologies. (5) This difference was also observed in another study. (1) This could indirectly indicate that patients with primary neurotropic viral infections develop alteration in sensorium earlier and may have a shorter onset to reporting period as compared to the patients having non viral aetiology of acute febrile encephalopathy. This finding has not been confirmed in any prospective study and can at best be a soft pointer towards the aetiology.

### **Etiological agents**

Various studies have documented different etiological agents responsible for acute febrile encephalopathy. (1,5,8) It is evident that both infectious and non infectious causes may result in similar presentation. (1,8) Primary CNS infections constitute majority of the cases of AFE to the tune of 60-80%, however, in India a variety of other diseases can also present with primary CNS involvement. (1,8)

CNS infection with neurotropic viruses is the commonest aetiology in some of the reported series (2) where as acute pyogenic meningitis has been reported in others. (1,5) This difference could be due to the difference in study design, the seasonal variation during the study period or the difference in the setup where the data has been collected. Amongst the neurotropic viruses, herpes simplex virus, flaviviruses (Japanese encephalitis) and enterovirus being commonest. (1,5,7,8)

According to the published literature important viruses causing acute viral meningitis are coxsackie, echoviruses, and polioviruses, especially in children. In adults, arboviruses and respiratory viruses such as adenoviruses, mumps, and HIV can cause aseptic meningitis (9). Other viruses causing acute viral encephalitis / AES are cytomegalo virus, Epstein barr virus, influenza, parainfluenza, mumps, measles, rubella, rabies, west Nile Virus, Kyasanur Forest disease virus, chikungunya, chandipura and paramyxoviruses ( Nipah) (10)

Most of the studies have shown JE and HSV to be the commonest viruses along with enteroviruses. (1,5,8) In one study CSF serology for West-Nile virus, measles, mumps, Chandipura virus and Nipah virus was negative in all patients screened. This indicates that these are not the common viral isolates in Indian patients with AES, however, they should not be forgotten. (5)

It is important to note that the exact aetiology may not be established in 11-15% of the cases with AFE. (1,8) It is also equally important to note that demonstration of viral antigens in CSF may not always be possible and may be undertaken in a research setting more often than as a routine test. (5) The exact diagnosis may also depend on the availability of a good laboratory backup with facilities to rule out common treatable causes. (1,5)

### Unusual causes one must never forget:

An important infectious cause, especially in a intensive care setup with infectious focus outside central nervous system is sepsis-associated encephalopathy (SAE). (1,8) SAE is a poorly understood CNS condition that is associated with a wide range of manifestations from lethargy to overt delirium in sepsis patients. Of note is the fact that, patients with SAE have higher mortality at 6 months, therefore it has serious prognostic implications, particularly who admitted to intensive care unit.(8) Since a large number of patients present to emergency in a tertiary care hospital with sepsis, it becomes an important differential diagnosis of AFE in adults. This must always be a consideration especially in elderly where focal signs of infections are missing and presentation could be simply with fever and altered sensorium (1,8)

Tuberculosis is rampant in India and in children is an important cause of acute febrile encephalopathy, (11) however, in adults it is not the case. (1,8) In adults tubercular meningitis may have an acute presentation but is more likely to have an intractable sub acute course rather than an acute presentation. (1) It should however, always be ruled out as it is treatable and the treatment duration in such cases would be longer. (1) Tuberculoma may occasionally present with fever, altered sensorium and focal seizures. (12) Usual presentation is subacute or chronic, however, occasionally acute onset may be reported by the relatives as worsening due to seizures is usually perceived as an acute event.

Cerebral abscess is another important cause which occur secondary to suppurative infection elsewhere in the body. The source may be within the skull (40%), metastatic (33%), or unidentified (20%). The main sources of metastatic abscess are from the heart, lung, and teeth. Clinical presentation is generally variable with focal and generalized seizures. The diagnosis should be considered early especially in patients presenting with focal deficits and seizures. (13)

Neuro cysticercosis (NCC) is a leading cause of epilepsy in developing countries. Altered sensorium is usual after seizure but fever may occasionally be present. (12,13) in some series NCC has been described as an important predisposing factor for JE and HSV infection. (15) The coexistence of these infections may confuse the clinical picture. (15)

An important cause, not to be missed is acute disseminated encephalomyelitis, which could be secondary to a CNS infection. (1)

A variety of free-living amoebas *Naegleria*, *Balamuthia mandrillaris* and *Acanthamoeba* are unusual causes of fever and altered sensorium. (13) The presentation is usually subacute but in an autopsy series from PGI, Chandigarh, it was found as an important cause of AFE which was missed, resulting in mortality. (unpublished data) The other unusual CNS infections missed are rabies and cytomegalovirus encephalitis. (unpublished data).

Other rare causes could be CNS fungal infections and neurosyphilis, but they usually have subacute/chronic presentation. (13)

**Non infectious causes:**

Amongst the non infectious causes, heat stroke, cortical venous thrombosis and neuroleptic malignant syndrome (NMS) should be kept in mind. (1) Heat stroke can be easily diagnosed by taking a good history. NMS is evident in patients having high grade fever, altered mentation with raised muscle enzymes in patients on antipsychotics, however, the exact history may not be available. In NMS, like in SAE, metabolic alterations and inflammatory cytokines may play an important role in the pathogenesis of encephalopathy rather than direct parenchymal involvement. (1)

Infracted tissue or thrombus could itself be a cause of fever and presence of large arterial or venous infarcts in central nervous systems can cause systemic inflammatory response syndrome (SIRS) resulting in fever and basic pathology in brain resulting in altered mentation. (1) Neurosarcoidosis generally has a sub acute presentation yet should be considered if non tubercular granulomatous inflammation is a clinical consideration. (13)

It is very important to take a detailed history of recreational drug intake as use of cocaine, amphetamines and even opium can lead to a presentation mimicking acute febrile encephalopathy. An important clue to this diagnosis would be presence of autonomic symptoms, commonly encountered with recreational drug use.

**In HIV positive patients:**

All common causes of AFE should be considered in immuno-compromised patients. (13) Bacterial, mycobacterial and parasitic infections of CNS are common in these patients. (13) Pyogenic meningitis and viral encephalitis can occur even in the absence of severe immune-suppression (15)

Acute pyogenic meningitis and extrapulmonary tuberculosis in the form of tubercular meningitis are the commonest bacterial infections. (£) Occurrence of parasitic and mycobacterial infection of the brain depends on a variety of factors, including treatment with highly active antiretroviral drugs and the patient's level of immune-suppression. An HIV-infected patient is at a high risk of developing opportunistic infections of the brain (often manifesting as multiple enhancing lesions) when the CD4+ count is <200 cells/ $\mu$ L. (13)

Amongst the parasitic infections, cryptococcal meningitis and cryptococcomas are the commonest CNS infections in HIV positive patients.

Intracranial mass lesions are frequently encountered in advanced stages of HIV infection., The common opportunistic infections include toxoplasmosis and tuberculoma, cryptococcoma, brain abscess and fungal granuloma. (13)(16)

Toxoplasmosis is a common cause of multiple intracranial mass lesions in patients with acquired immunodeficiency syndrome (AIDS). The characteristic imaging pattern in toxoplasmosis lesions is a ring-enhancing lesion made up of an eccentric nodule. In around 30% of the lesions, this enhancing nodule is found within and adjacent to the enhancing rim. (17) Most lesions in toxoplasmosis occur in basal ganglia and in frontal and parietal lobes.

Other infectious causes of fever and multiple ring-enhancing lesions of the brain in patients with HIV infection, could be cryptococcal abscesses and cryptococcomas. (12)

Unusual pathogens like *Nocardia* asteroids and fungal infections like *Candida* and aspergillosis could present with multiple cerebral septic infarctions and abscess formations in HIV positive patients. (18) Rhinocerebral mucormycosis, especially in diabetics may present acutely with altered mentation with a bout of fever.

### **Suggested workup:**

The workup of patients with acute febrile encephalopathy / acute encephalitic syndrome depends on the clinical probability of the diagnosis. The baseline investigations include haematological tests and chest x-ray are aimed at looking for evidence of SIRS. High counts in an elderly patient may indicate sepsis however; normal counts would not rule it out. (19)

Initial work up should be aimed at ruling out common causes of acute febrile encephalopathy in adults. Detailed peripheral smear examination to rule out presence of malarial parasite is indicated in every patient especially during monsoons in India. Rapid diagnostic tests is an important bedside tool in a busy ER. Recent guidelines do mention this as a safe and reliable option with rapid turn around time.(20) serological tests to rule of leptospirosis, dengue, Enteric fever and Scrub typhus are indicated in all patients with AFE, however, these a single test reading may not always be sufficient and a paired sample may be needed to confirm the diagnosis. (20). Where ever possible PCR to detect antigen in suspected infection may be useful but the results need to be carefully interpreted.

Chest X rays should always be done to rule out a pneumonia, especially in elderly and to look for any evidence of current or remote pulmonary tuberculosis. Chest X ray demonstrating imaging findings consistent with tuberculosis may be an important supportive evidence Detailed radiological imaging with CT scan or high resolution CT scan of chest should be reserved for patients with high index of suspicion. (20)

CSF examination is a crucial investigation in patients with AFE, (1,5,6,8) however, through clinical examination to rule out raised intracranial pressure is indicated before a lumbar puncture is undertaken. (21) Simple examination of fundus would pick up raised intracranial pressure. No evidence of papilloedema may not be sufficient to rule it out. Look out for neck stiffness, cranial nerve palsies (6th cranial nerve) and presence of focal deficits. Lumbar puncture is contraindicated if any of these signs are present. (21,22)

In a busy emergency a non contrast Computerised tomogram (NCCT) of head can be a screening tool for ruling out raised ICP. (22, 23) Lumbar puncture is contraindicated if CT scan shows the evidence of lateral midline shift, loss of suprachiasmatic or basal cisterns, fourth ventricle effacement, obliteration of supracerebellar or quadrigeminal plate cisterns with patent ambient cisterns. (22)

NCCT brain may pick up focal calcification and space occupying ring lesions which may be suggestive of tuberculoma, neurocysticercosis, toxoplasma, cerebral abscess or ADEM. At

times these findings are better appreciated after contrast. (23) CT scan is able to detect cerebral abscesses greater than 1 cm in diameter. (12)

In acute set up, NCCT can be fairly non specific and an magnetic resonance imaging (MRI) study can provide a clue to diagnosis. (23) One should be aware that the MRI facility may not be available at all the centres and the test involves considerable cost and time. In a critically ill patient, it may not be possible to do this as a baseline investigation, although its diagnostic yield is better than NCCT head. (23) Once the patient is haemodynamically stable, a properly done MRI scan can pick up subtle changes in the brain parenchyma in patients with encephalitis and basal meningeal enhancement. (22) NCC and tuberculomas are better picked up MRI especially after gadolinium enhancement. (12,13)

Cerebrospinal fluid should always be examined in patients with acute febrile encephalopathy as it provides important clues to the diagnosis. (1,5,6,8,20,23) CSF should be examined for cells, sugars and specific serological tests, PCR for commonly encountered viruses can rule out common neurotropic viral infections. (1,5,8,20) It is very important to know the epidemiology of the common viruses causing encephalitis in the region, seasonal variation and their clinical presentation. (1,5,8,11,20) Focused examination for commonly treatable viruses may be justified for treatment propose, however, a panel of investigations can be performed if unusual symptoms or presentations are encountered. (2,7) Since TB is endemic in India and can have acute presentation it is advisable to send CSF for tests to rule in or rule out tuberculosis. (1,8) These tests may include CSF for adenosine deaminase test and Tb PCR where ever available. Since this could have implication on treatment, it should be a rule rather than exception.

Specific tests for neurocysticercosis, toxoplasmosis and other unusual viral / parasitic infections can be performed if the routine screening is not yielding any results.

### **Management :**

Since a variety of organism can cause similar presentation, routine investigations may give non specific results and the turn around time for many investigations (serology, PCR) may be longer. It is important to initiate empiric treatment based on the commonly encountered causes of AFE. (1,5,8,20) It is important to cover all treatable and potentially life threatening causes upfront. (8) Since malaria is no longer the most important cause of AFE (1,5,8) It is impractical to prescribe empiric anti malarial drugs to all patients with AFE. (8) With the availability of good quality RDTs having good negative predictive value for ruling out malarial infection bed side, the most practical approach would be to rule it out by bedside RDTs. (20). Starting treatment with Acyclovir (covering for herpes simplex) and third generation cephalosporins (covering enteric fever, leptospirosis, scrub typhus) would take care of all the life threatening infections. (20) Further management can be guided by the available investigations.

Although tuberculosis and neurocysticercosis are endemic in India, yet, there is no justification in starting empiric treatment for any exotic / unusual organisms. Till the time a definitive diagnosis is available, supportive treatment is all that is required.

Surgical intervention may be necessary in patients with cerebral abscess, if deterioration occurs. (12)

The treatment for raised intracranial hypertension can be initiated as soon as the patient is brought in. control of fever, hypoxia, sedation, control and prevention of seizures are important interventions.(24) Fever can be controlled by antipyretics or cold sponging. Oxygen supplementation and treatment for anaemia will take care of hypoxia. Sedation and paralysis with mechanical ventilation (hyperventilation) may be needed in some patients. (24)

Mannitol and hypertonic is the most commonly used hyperosmolar agent for the treatment of intracranial hypertension. The relative effectiveness of these two hyperosmotic agents is more or less similar. (24)

Intravenous bolus administration of mannitol lowers the ICP in 1 to 5 minutes with a peak effect at 20 to 60 minutes. The effect of mannitol on ICP lasts 1.5 to 6 hours, depending on the clinical condition (25). Mannitol usually is given as a bolus of 1 g/kg body weight as urgent reduction of ICP is normally needed. For long-term reduction of ICP is needed, 0.25 to 0.5 g/kg can be repeated every 2 to 6 hours Adequate fluid replacement si needed for mannitol-induced diuresis. It si contraindicated in presence of dehydration and renal dysfunction. Mannitol should always be tapered to prevent a rebound in cerebral edema and ICP.

Hypertonic saline is usually given in concentrations of 3% to 23.4%. It creates an osmotic force to draw water from the interstitial space of the brain parenchyma into the intravascular compartment in the presence of an intact blood-brain barrier, reducing intracranial volume and ICP. (24,26) Hypertonic saline has a clear advantage over mannitol in hypovolemic and hypotensive patients. As it augments intravascular volume and may increase blood pressure in addition to decreasing ICP. One should always monitor hematologic and electrolyte functions as it can cause bleeding secondary to decreased platelet aggregation and prolonged coagulation times, hypokalemia, and hyperchloremic acidosis (26). Hyponatremia should be excluded before administering hypertonic saline to reduce the risk of central pontine myelinolysis.(27).

Steroids are commonly used for raised ICP secondary to primary and metastatic brain tumors, to decrease vasogenic cerebral edema.(28) They can also be used to treat inflammatory edema secondary to tubercular meningitis, neurocysticercosis and toxoplasmosis (20). The most commonly used regimen is intravenous dexamethasone, 4 mg every 6 hours.

For etiological conditions like CVT and NMS, specific therapy may be needed after the diagnosis is established.

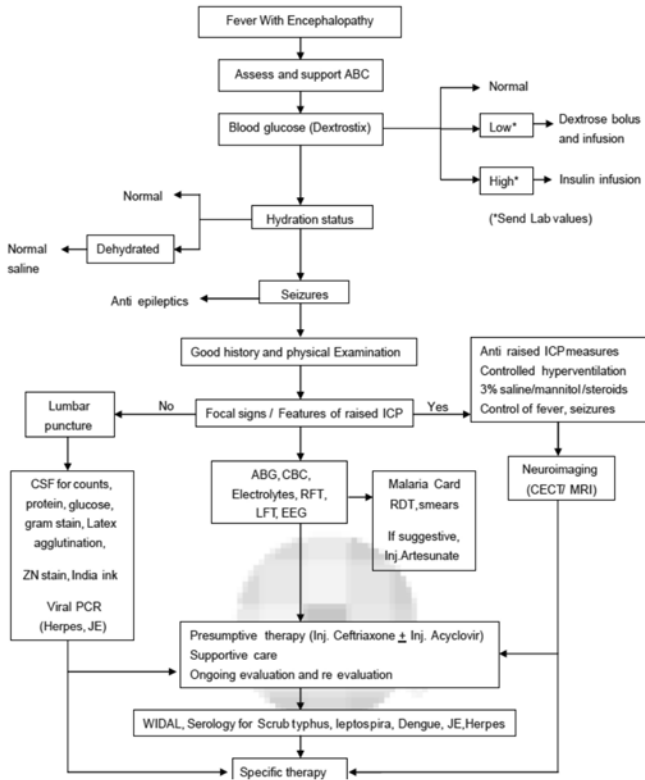
## Prognosis

Many acutely ill febrile patients with encephalopathy may make complete recovery once the underlying cause is treated but considerable skill is required to correctly diagnose the underlying aetiology. A small number of patients might still be left with left with neurologic sequel. (1,8) Delayed neurologic recovery and sequel are well described with viral meningoencephalitis not eminently treatable. (2,3) Mortality in patients with SAE and other tropical infections is mainly

contributed by multiorgan dysfunction. Raised intracranial pressure could also contribute to mortality in patients with primary parenchymal brain involvement.(1,8) In patients with cerebral abscess, course remains unpredictable and the mortality rate is high approximately 20%.(12)

In around 10-15% patients a definitive diagnosis may not be achievable and mortality is high in these patients. (1)

**Tables 1: Approach to a patient with acute febrile encephalopathy**



Adapted from Tropical fevers: Management guidelines. Indian J Crit Care Med. 2014 Feb;18(2):62-9.



**Table 2: Uncommon infections resulting in acute febrile encephalopathy**

Viruses	Coxsackie, echoviruses, and polioviruses	
	cytomegalovirus	
	Epstein barr virus,	
	influenza, parainfluenza,	
	mumps, measles, rubella,	
	rabies	
	chikungunya,	
Very rare	West Nile Virus, Kyasanur Forest disease virus, chandipura paramyxoviruses ( Nipah)	
	Bacteria	Mycobacterial
		Brucella (neurobrucellosis)
Nocardia asteroidis		
Parasites	Cryptococcal	
	Toxoplasma	
	Naegleria,	
	Balamuthia mandrillaris	
	Acanthamoeba	
Fungus	Candida	
	Aspergilosis	
	Mucormycosis (rhino-cerebral)	
Others	Sepsis associated encephalopathy (SAE)	
	Cerebral abscess	

**Table 3: Important non infectious causes of acute febrile encephalopathy**

Aetiology
Heat stroke
Malignant hyperthermia
Acute disseminated encephalomyelitis
Toxic causes
Serotonin syndrome
Cocaine, amphetamine toxicity
Ecstasy intoxication
Salicylate poisoning
Cortical venous thrombosis
Neuroleptic malignant syndrome
Thyrotoxic encephalopathy
Neurosarcoidosis

## References

1. Ashish Bhalla, Vika Suri, Subhash Varma, Navneet Sharma, Sushil Mahi, Paramjeet Singh, Niranjana K Khandelwal. Acute febrile encephalopathy in adults. *J Emerg Trauma Shock*. 2010 Jul-Sep; 3(3): 220–224.
2. Chaudhari A, Kennedy PG. Diagnosis and treatment of Viral encephalitis. *Postgrad Med J*. 2002;78:575–83.
3. Clinque P, Cleator GM, Weber T, Monteyne P, Sindic CJ, Van Loon AM. The role of laboratory investigations in the diagnosis and management of patients with suspected herpes simplex encephalitis: a consensus report. *J Neurol Neurosurg Psychiatry*. 1996;61:339–45.
4. Kennedy PG, Chaudhary A. Herpes simplex encephalitis. *J Neurol Neurosurg Psychiatry*. 2002;73:237–8.
5. Rajnish Joshi. Clinical presentation, etiology, and survival in adult acute encephalitis syndrome in rural Central India *Clin Neurol Neurosurg*. 2013 September ; 115(9): 1753–1761.
6. Saminathan M, Karuppanasamy K, Pavulraj S, Gopalakrishnan A, Rai RB. Acute Encephalitis Syndrome - A Complex Zoonotic Disease. *International Journal of Livestock Research* 2013;3 (2): 174-78.
7. D.S.Dinesh, K. Pandey, V.N.R. Das, R.K.Topno, S.Kesari, V. Kumar, A. Ranjan, P. K. Sinha and P. Das. Possible factors causing Acute Encephalitis Syndrome outbreak in Bihar, India. *Int.J.Curr.Microbiol.App.Sci* (2013) 2(12): 531-538

8. Modi A, Atam V, Jain N, Gutch M, Verma R. The etiological diagnosis and outcome in patients of acute febrile encephalopathy: a prospective observational study at tertiary care center. *Neurol India*. 2012 Mar-Apr; 60(2):168-73.
9. Kumar R. Aseptic meningitis: diagnosis and management. *Indian J Pediatr*. 2005;72(1):57–63.
10. Handique SK. Viral infections of the central nervous system. *Neuroimaging Clin N Am*. 2011;21:777–94.
11. Karmarkar SA, Aneja S, Khare S, Saini A, Seth A, Chauhan BK. A study of acute febrile encephalopathy with special reference to viral etiology. *Indian J Pediatr*. 2008;75:801–5. [PubMed]
12. Joshua SP, Mahapatra AK. Epilepsy in tropics: Indian perspective. *J Neurosci Rural Pract* 2013;4:171-5.
13. Garg R K, Sinha M K. Multiple ring-enhancing lesions of the brain. *J Postgrad Med* 2010;56:307-16
14. Handique SK1, Das RR, Saharia B, Das P, Buragohain R, Saikia P. Coinfection of Japanese encephalitis with neurocysticercosis: an imaging study. *AJNR Am J Neuroradiol*. 2008 Jan;29(1):170-5.
15. National AIDS Control Organization, Ministry of Health and Family Welfare, Government of India (2000): *Surveillance for HIV Infections/AIDS Case in India (1986 - 1999)*. New Delhi, India.
16. Guerrant RL, Walker DH, Weller PF. (Eds) *Essentials of Tropical Infectious Diseases*. New York: Churchill Livingstone, 2001.
17. Ramsey RG, Gean AD. Neuroimaging of AIDS. I. Central nervous system toxoplasmosis. *Neuroimaging Clin N Am* 1997;7:171-86.
18. Gabelmann A, Klein S, Kern W, Krüger S, Brambs HJ, Rieber-Brambs A, et al. Relevant imaging findings of cerebral aspergillosis on MRI: a retrospective case-based study in immunocompromised patients. *Eur J Neurol* 2007;14:548-55.
19. Aird WC. The hematologic system as a marker of organ dysfunction in sepsis. *Mayo Clin Proc*. 2003 ;78(7):869-81.
20. Singhi S1, Chaudhary D2, Varghese GM3, Bhalla A4, Karthi N5, Kalantri S6, Peter JV7, Mishra R8, Bhagchandani R9, Munjal M10, Chugh TD11, Rungta N12. *Tropical fevers: Management guidelines*. *Indian J Crit Care Med*. 2014 Feb;18(2):62-9.
21. Ely EW, Shintani A, Truman B, Speroff T, Gordon SM, Harrell FE, et al. Delirium as a predictor of mortality in mechanically ventilated patients in intensive care unit. *JAMA* 2004;292:753-62
22. D Roytowski, A Figaji, *Raised intracranial pressure: What it is and how to recognise it*. *CME* 2013; 31(3)
23. Bhalla A, Suri V, Singh P, Varma S, Khandelwal N. Imaging in adult patients with acute febrile encephalopathy: what is better computerized tomography or magnetic resonance imaging. *Indian J Med Sci*. 2011 May; 65(5):193-202.
24. Leonardo Rangel-Castillo, Shankar Gopinath, Claudia S. Robertson. *Management of Intracranial Hypertension*. *Neurol Clin*. May 2008; 26(2): 521–541
25. Knapp JM. *Hyperosmolar therapy in the treatment of severe head injury in children: mannitol and hypertonic saline*. *AACN Clin Issues*. 2005;16:199–211.
26. Doyle JA, Davis DP, Hoyt DB. *The use of hypertonic saline in the treatment of traumatic brain injury*. *J Trauma*. 2001;50:367–83.

27. Bratton SL, Chestnut RM, Ghajar J, et al. Hyperosmolar Therapy. *J Neurotrauma*. 2007;24(supplement 1):S-14–S-20.
28. Kaal EC, Vecht CJ. The management of brain edema in brain tumors. *Curr Opin Oncol*. 2004;16:593–600.