

**DEFINITION**

The interstitial lung diseases (ILD) are a group of disorders that predominantly, but not exclusively involve the lung interstitium. The term ILD is imprecise clinical term for a diverse range of diseases that involve inflammation and fibrosis of the alveoli, distal airways, and septal interstitium of the lungs. The lungs are affected in three ways. The lung tissue is damaged in some known or unknown way, followed by inflammation of the alveolar wall, and finally there is fibrosis in the interstitium that results in end stage lung. The stiff lungs cause a restrictive type of functional abnormality and affect gas exchange.

The prevalence of ILD in several countries has increased over time. The causes of ILD are many. Despite significant improvement in our knowledge of pathogenesis of ILD, the etiology of a large number of cases remains unknown and these are called the idiopathic interstitial pneumonias (IIPs). Idiopathic pulmonary fibrosis (IPF) is the commonest example of this group.

**DIAGNOSIS OF ILD (BOX 1)****Clinical Features**

Dry cough and dyspnoea are the main symptom of ILD. Symptoms of the associated disorders like RA, scleroderma, sarcoidosis may be present. When the disease is severe and prolonged, symptoms of right heart failure may occur. Clubbing is a feature of IIPs. Pallor due to anemia of chronic inflammation may also be present in most cases. Raynaud's phenomenon, sclerodactyly, and telangectasia are seen with the CTD. Skin, eye, bone and joint involvement and hepato-splenomegaly are features of sarcoidosis. The findings of respiratory system examination are fine, bibasilar, and end inspiratory crackles also called "velcro rales".

**Box 1: Diagnosis of ILD**

- Dry cough
- Progressive dyspnoea
- Exercise desaturation
- Clubbing
- Fine, bibasilar, end inspiratory ("Velcro") crackles
- CXR showing reticular/ nodular opacities
- Spirometry showing restrictive abnormality, reduced DLCO
- Features of associated disorders like RA, SLE, SS, sarcoidosis
- Later stages features of right heart failure

**Investigations**

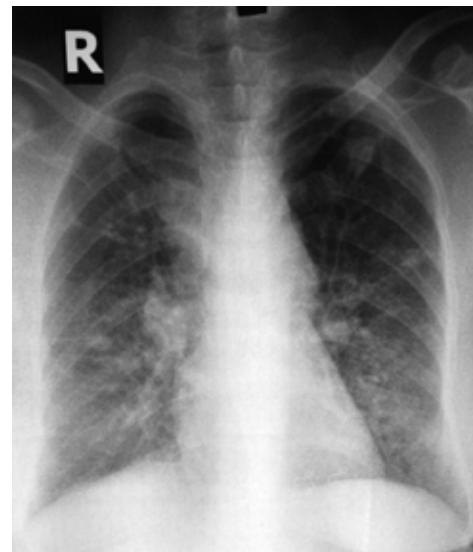
Chest X-ray, pulmonary function tests, and blood tests are important baseline tests. High-resolution computerized tomography (HRCT) is an important new diagnostic tool in the evaluation of ILD. Lung biopsy, trans-bronchial (TBLB) or open (OLB) may be required for diagnosis and to predict response to therapy in some cases. To monitor disease progression and response to therapy symptoms, PFT and 6 MWT are used.

**Laboratory Tests**

The routine laboratory tests are not very useful for diagnosis of ILD except in few cases. Total and differential white cell count (WBC) to diagnose eosinophilia, along with liver and renal function tests should be performed in all cases of ILD. Rheumatoid arthritis (RA) factor, lupus erythematosus (LE) cells, antinuclear antibody (ANA) anti double stranded DNA (dsDNA) are positive in collagen vascular disorders and also in cases of IPF. Positive cytoplasmic anti neutrophilic cytoplasmic antibody (C-ANCA) is diagnostic for WG. Serum angiotensin converting enzyme (SACE) is positive in 75% of cases of sarcoidosis but is neither specific nor useful for monitoring response to therapy.

**Chest Radiograph**

The chest radiograph helps to confirm the clinical diagnosis and in some cases certain radiographic patterns (Box 2) are helpful in establishing a specific diagnosis. The chest radiographs in cases of ILD typically show an "interstitial" pattern (Figure 1).



**Fig. 1: X-ray chest showing interstitial lung disease**

## Box 2: Helpful Chest Radiograph Patterns

- **Upper zone predominance:** hypersensitivity pneumonitis, sarcoidosis, silicosis, coal workers pneumoconiosis, berylliosis, ankylosing spondylitis, rheumatoid arthritis, radiation fibrosis and drug induced (gold, amiodarone)
- **Lower zone predominance:** asbestosis, scleroderma, IPF
- **Miliary pattern:** miliary TB, metastasis from adenocarcinoma, malignant melanoma, hypernephroma
- **Hilar/ mediastinal lymphadenopathy:** sarcoidosis, miliary TB, lymphoma, lymphangitis carcinomatosa, berylliosis
- **Pleural involvement:** RA, SLE, scleroderma and mixed connective tissue disorders, asbestosis, lymphangitis carcinomatosa, drug induced ILD (nitrofurantoin), sarcoidosis (rare), and radiation pneumonitis ( due to lymphatic blockage)

### High Resolution Computed Tomography (HRCT)

The HRCT is a most useful diagnostic test available for evaluation of ILD. The findings are sufficiently specific in some cases to be diagnostic. It is also useful to assess the extent of pulmonary, pleural and mediastinal involvement and to guide lung biopsy.

### Pulmonary Function Tests and Arterial Blood Gas (ABG) Analysis

Simple spirometry is adequate for initial evaluation and subsequent follow up. Reduced forced vital capacity (FVC) with a normal ratio of forced expiratory volume in 1 second (FEV1) to FVC (FEV1 /FVC) suggests a restrictive abnormality. Diffusion capacity of lung for carbon monoxide (DLCO) is reduced.

### Electrocardiography (ECG) and Echocardiography (ECHO)

The findings of p pulmonale, right axis deviation, R /S ratio >1 in V1, ST depression and T wave inversion in V1-V4, and incomplete or complete right bundle branch block on electrocardiography (ECG) identify presence of pulmonary hypertension and cor pulmonale. 2-D ECHO should be performed to confirm pulmonary hypertension and cor pulmonale.

### Tuberculin Skin Test (TST)

Tuberculin Skin Testing or Mantoux (MT) testing is important for several reasons in cases of ILD. It may serve as an aid to diagnosis of miliary TB, although in these cases it is often negative due to anergy. Negative MT test supports the diagnosis of sarcoidosis although reports from India suggest that positive test is not incompatible with the diagnosis of sarcoidosis. Positive test is important to initiate isoniazid (INH) prophylaxis along with corticosteroid therapy in cases of ILD. In cases of sarcoidosis a nodule may develop at the site of MT test at 6 to 8 weeks, which can be used for histological confirmation.

## TREATMENT OF INTERSTITIAL LUNG DISEASES

The most important aspect of treatment of the ILD is

early diagnosis and removal of the offending / inciting agent, if identifiable. Specific treatment can be offered in cases of infective etiology e.g. TB. Early treatment with corticosteroids to reverse the inflammation is vital. In advanced cases symptomatic treatment to provide relief, preventive vaccines to reduce pulmonary infections, oxygen therapy and physical and occupational rehabilitation can be offered to the patients. Lung transplantation (single or double) can be performed in end stage lung, if facilities for the same are available.

### Idiopathic Interstitial Pneumonias (IIPs)

When all known causes of interstitial lung disease have been ruled out, the condition is called idiopathic interstitial pneumonias (IIP). Idiopathic Pulmonary Fibrosis (IPF) is the most common variety of the IIPs. It is classified as UIP (usual interstitial pneumonitis), DIP (desquamative interstitial pneumonitis) and NSIP (non-specific interstitial pneumonitis). AIP (acute interstitial pneumonia) is a rapid fulminant form of IIP with poor response to therapy and about 90 % mortality.

A correct histological classification is of utmost importance based on the fact that prognosis and survival vary largely depending on the subset of IIP. Pathology-based diagnoses are, however, only available in a minority of patients with IIP, since the majority do not undergo surgical lung biopsy. Conversely, it has been shown that high-resolution computed tomography (HRCT) scanning, in particular, but also other clinical features, may be of discriminative diagnostic value. Therefore, integrated clinical, radiological and histological classifications and definitions are mandatory. In response to this, the American Thoracic Society (ATS) and the European Respiratory Society (ERS) recently (2013) published an international consensus statement on IIP (Box 3). The characteristic histopathological features of UIP are a heterogeneous appearance with alternating areas of normal lung, interstitial inflammation, fibrosis, and honeycombing. The changes are most severe sub-pleurally and there is temporal heterogeneity such that the pathological processes are at different stages of development. The term IPF is now restricted to the specific condition characterised by the histopathological pattern of UIP.

The different types of IIP need to be recognized because of important implications of treatment and prognosis. DuBois has raised the issue of “discordant” pathology. This concept pertains to 2 different pathologies, usual interstitial pneumonia (UIP) and nonspecific interstitial pneumonitis (NSIP), being found in the same patient who has been biopsied (appropriately) at multiple sites. In such situations, patients behave as if they have the worst of the 2 diagnoses, and UIP becomes the default diagnosis. The characteristic features of IPF are dry cough and progressive dyspnoea usually of some year’s duration, clubbing and bibasilar crackles. The chest radiograph shows a reticulonodular pattern predominant at lung bases. This may be associated with reduction of lung volumes and later typical “honey comb” lung.

**Box 3: Revised Classification of IIP (ATS/ERS13)****Major Idiopathic Interstitial Pneumonia**

Chronic Fibrosing IP: IPF and Fibrotic NSIP

Smoking –related IP: RBILD and DIP

Acute/Subacute IP: COP and AIP

**Rare Idiopathic Interstitial Pneumonia**

Idiopathic lymphoid interstitial pneumonia

Idiopathic pleuroparenchymal fibroelastosis

Rare histological variants

Acute fibrosing organising pneumonia (AFOP)

Airway centered interstitial fibrosis (ACIPF)

**Unclassifiable Idiopathic Interstitial Pneumonias**

Evidence of pulmonary hypertension and cor pulmonale may be present in the form of enlargement of the right descending pulmonary artery and the cardiac size.

High resolution computed tomography (HRCT) findings are characteristic. These are presence of ground glass opacification suggestive of alveolitis along with simultaneous presence of fibrosis and honey combing. This feature where different stages of disease active and inactive are present simultaneously is called as loss of temporal relationship and is typical of UIP/IPF. The distribution of lesions is typically subpleural and in the lower lobes (Figure 2). In advanced disease “honey comb” cysts are seen throughout the lungs (Figure 3a and 3b). These features are also seen in AIPF and asbestosis, which can be excluded by history and clinical examination. Pulmonary function test (PFT) must include spirometry and shows a restrictive abnormality indicated by reduced FVC with a normal FEV1 /FVC. DLCO is reduced though this is not diagnostic. Reduction in arterial oxygen PaO<sub>2</sub> as also increase in alveolar arterial gradient (PAO<sub>2</sub>-PaO<sub>2</sub>) particularly after exercise is commonly seen. Post exercise oxygen desaturation has been demonstrated to predict survival.<sup>14</sup> 2-D ECHO with colour Doppler should be performed to assess pulmonary hypertension and cor pulmonale, if possible. Lung biopsy, transbronchial (TBLB) or open (OLB) may be required under certain circumstances (Box 4).

Treatment of UIP/IPF the most common variety of IIP (ATS/ERS/JRS/ALAT Statement 2011) incorporates the antifibrotic molecules Pirfenidone and Nintedanib. These have largely replaced the previous therapy involving steroids and immunosuppressants. This radical change is based on the recent insights pertaining to that pathophysiology of the condition which emphasizes underlying oxidative stress and pulmonary fibrosis as the culprits rather than inflammation as previously believed. Treatment of pulmonary hypertension in IPF is controversial because of scarce evidence available regarding its efficacy. Pulmonary rehabilitation, oxygen therapy and lung transplantation have a documented beneficial role in terms of improvement in the quality of life. No therapy has shown to have proven favourable

**Box 4: Indications for Lung Biopsy in Interstitial Lung Disease**

- Age <65 years
- Presence of systemic symptoms like fever and weight loss
- Extrapulmonary manifestations like hemoptysis, peripheral vasculitis and unexplained pulmonary hypertension
- Absence of family history
- Atypical radiographic features like nodular or patchy opacities superimposed on interstitial pattern, hilar or mediastinal lymphadenopathy, pleural effusion or rapid progression of lesions
- Rapid deterioration of pulmonary functions.

effects as far as survival is concerned. However, some IIPs such as NSIP and DIP may respond well to therapy with oral corticosteroids e.g. prednisolone given in the dose of 1 mg/kg/day.

Follow up of cases is best done clinically and by spirometry. Response to treatment is defined in terms of change in PFT as follows i) Improved if increase of >10% in FVC or TLCO without decrease of >10% in either ii) Unchanged if increase or decrease by, 10% in FVC and DLCO; or increase of >10% in FVC or DLCO with decrease of >10% in the other and iii) Worse if decrease of >10% in FVC or DLCO without increase of >10% in either.

Oxygen therapy should be prescribed for some patients with IPF, particularly those cases with hypoxaemia at rest, presence of pulmonary hypertension and cor pulmonale and exercise induced or nocturnal desaturation. Pneumococcal vaccine and yearly influenza vaccine may help prevent infections. Pulmonary rehabilitation and education programs help to improve the quality of life. Although, currently not available in India, lung transplantation offers hope for selected people with severe IPF and other advanced ILDs. The Gender Age Physiology (GAP) risk assessment system is a clinical prediction tool that estimates prognosis in patients with IPF (GAP-IPF) and ILDs (ILD-GAP).

**ACUTE EXACERBATION OF IPF**

Some patients of IPF suffer from acute deteriorations of unknown etiology with periods of relative stability. These have been termed acute exacerbations of IPF. Acute exacerbations of IPF are defined as acute, clinically significant deteriorations of unidentifiable cause in patients with underlying IPF. Proposed diagnostic criteria include subjective worsening over 30 days or less, new bilateral radiographic opacities, and the absence of infection or another identifiable etiology. Clinical features consist of cough, fever, and flulike symptoms severe hypoxemia, and respiratory failure that may require mechanical ventilation. Treatment of acute exacerbation of IPF has generally consisted of high-dose corticosteroids, but there are no data from controlled trials to prove their efficacy. Mortality rates range from 20 to 86%.

## REFERENCES

1. Hutchinson J, Fogarty A, Hubbard R, McKeever T. Global incidence and mortality of idiopathic pulmonary fibrosis: A systematic review. *Eur Respir J* 2015; 46:12.
2. Vij R, Strek ME. Diagnosis and Treatment of Connective Tissue Disease-Associated Interstitial Lung Disease. *Chest* 2013; 143:814-824.
3. Travis WD, Costabel U, Hansell DM. An official american thoracic society/european respiratory society statement: Update of the international multidisciplinary classification or the idiopathic interstitial pneumonias. *Am J Respir Crit Care Med* 2013; 188:733–748.
4. Mueller-Mang C, Grosse C, Schmid K, Stiebellehner L, Bankier AA. What every radiologist should know about idiopathic interstitial pneumonias. *Radiographics* 2007; 27:595-615.
5. Raghu G, Collard HR, Egan JJ, Martinez FJ, Behr J, Brown KK et al. An Official ATS/ERS/JRS/ALAT Statement: Idiopathic Pulmonary Fibrosis: Evidence-based Guidelines for Diagnosis and Management. *Am J Respir Crit Care Med* 2011; 183:788–824.
6. Maheshwari U, Gupta D, Aggarwal AN, Jindal SK. Spectrum and diagnosis of idiopathic pulmonary fibrosis. *Indian J Chest Dis Allied Sci* 2004; 46:23-6.
7. Bradley B, Branley HM, Egan JJ, Greaves MS, Hansell DM, Harrison NK, et al. Interstitial lung disease guideline: the British Thoracic Society in collaboration with the Thoracic Society of Australia and New Zealand and the Irish Thoracic Society. *Thorax* 2008; 63 Suppl 5:v1-58.
8. Ley B, Ryerson CJ, Vittinghoff E, Ryu JH, Tomassetti S, Lee JS et al. A multidimensional index and staging system for idiopathic pulmonary fibrosis. *Ann Intern Med* 2012;156:684-691. Wells A U, Kokosi M, Karagiannis K. Treatment strategies for idiopathic interstitial pneumonias. *Curr Opin Pulm Med* 2014; 20:442–448
9. Ley B, Ryerson CJ, Vittinghoff E, Ryu JH, Tomassetti S, Lee JS, et al. A Multidimensional Index and Staging System for Idiopathic Pulmonary Fibrosis. *Annals of Internal Medicine* 2012; 156:684-91.
10. Ryerson C, Vittinghoff E, Ley B, Lee J, Mooney J, Jones K et al. Predicting Survival Across Chronic Interstitial Lung Disease. *Chest* 2014; 145:723-728.