

Life-threatening Supraventricular Arrhythmias: Management Issues

BALBIR SINGH

The cardiac tachyarrhythmias can be divided into 2 major groups.

- A. Supraventricular
- B. Ventricular

The **supraventricular tachyarrhythmias**, commonly seen in clinical practice are:

1. Supraventricular tachycardias.
2. Atrial flutter
3. Atrial fibrillation

Supraventricular arrhythmias can be life threatening

- a. When associated with underlying LV dysfunction heart failure.
- b. In association with WPW syndrome where rapid conduction across the accessory pathway may lead to rapid ventricular rates.
- c. In association with incessant atrial tachycardia which can lead to LV dysfunction and tachycardiomyopathy.

Supraventricular Tachycardias

The term “supraventricular tachycardia” SVT refers to paroxysmal tachyarrhythmias, which require atrial or atrioventricular nodal tissue, or both, for their initiation and maintenance. Supraventricular tachycardias are often recurrent, occasionally persistent, and a frequent cause of visits to emergency rooms and primary care physicians. Common symptoms of supraventricular tachycardia include palpitations, anxiety, light-headedness, chest pain, pounding in the neck and chest, and dyspnea

Most types of tachycardia have a reentry mechanism (Figs 1A to C) and they are classified according to the

location of the reentry circuit. Approximately 60% of cases are due to an atrioventricular nodal reentry circuit, and about 30% are due to an atrioventricular reentry circuit mediated by an accessory pathway — a short muscle bundle that directly connects the atria and ventricles. Atrial tachycardia comprises about 10% of cases and often has a focal origin.

Table 1: Supraventricular tachycardia

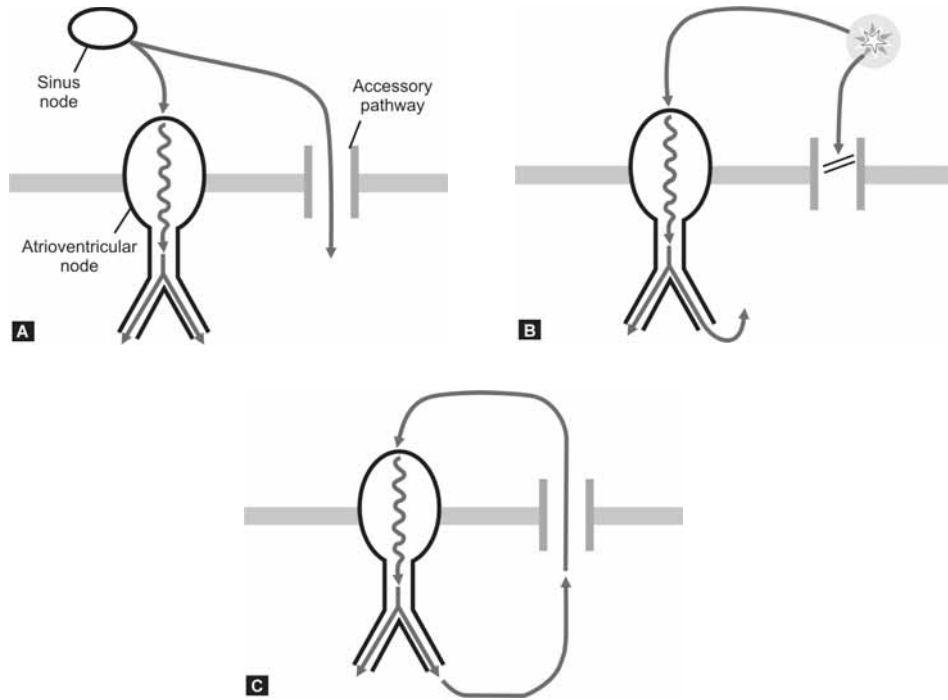
- | |
|---|
| 1. Atrioventricular nodal reentry (AVNRT) |
| 2. Atrioventricular reentry <ol style="list-style-type: none"> a. Accessory pathway mediated. b. Permanent form of junctional reciprocating tachycardia (PJRT) - usually seen in children |
| 3. Atrial tachycardia |

Table 2: Causes of wide QRS tachycardia

- | |
|---|
| 1. Ventricular tachycardia |
| 2. Supraventricular tachycardia with aberrancy |
| 3. Supraventricular tachycardia with underlying bundle branch block |
| 4. Antidromic tachycardia in patients with WPW syndrome |

AV nodal reentry (Fig. 2) is the most common mechanism of supraventricular tachycardias, comprising 60% of all supraventricular tachycardias. The supraventricular tachycardia usually have narrow QRS complex unless associated with aberrancy. The EKG features which help to distinguish various forms of supraventricular tachycardia are:

- a. *Relationship of atrial and ventricular events:* Presence of atrial activity and AV relationship help to distinguish reentrant tachycardia from atrial



Figs 1A to C: An impulse (Panel A, arrows), initiated normally in the sinus node, passes through two pathways — for example, the atrioventricular nodal connection and an accessory pathway. A premature atrial impulse (Panel B) occurs and reaches the accessory pathway when it is still refractory but conduction can occur in the atrioventricular node. The impulse takes sufficient time to circulate through the atrioventricular node and across the ventricle to allow the accessory pathway to recover its excitability and conduct the impulse back to the atrium (Panel C). The wave front reenters the atrioventricular node, continually encounters excitable tissue, and is perpetuated as a reentry circuit

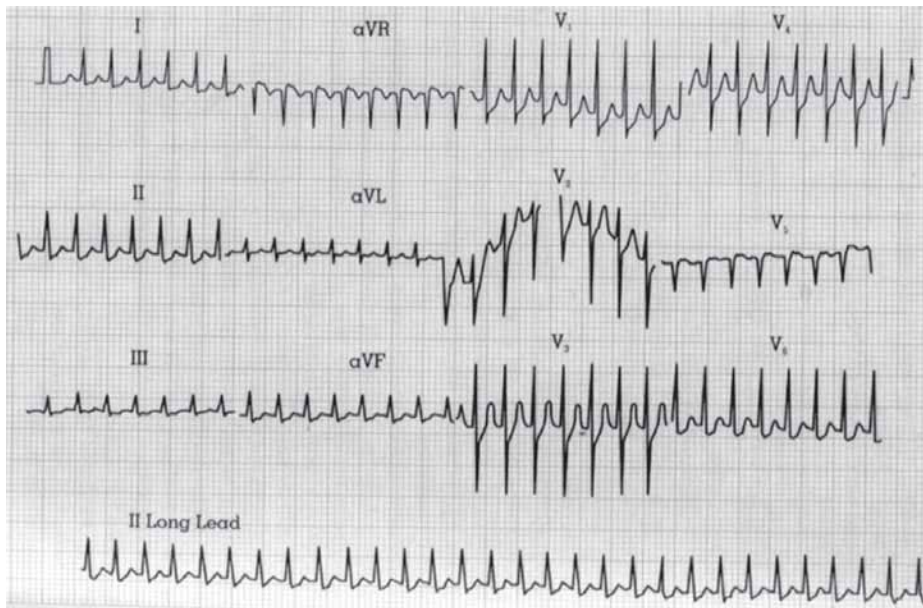


Fig. 2: 12 lead electrogram in a 56 years old lady shows a narrow QRS tachycardia with P waves which cannot be clearly seen. There is a suggestion of a pseudo S wave in LII and a pseudo r wave in V1 resulting from the retrograde P wave. This is consistent with atrioventricular nodal reentry

tachycardias. Reentrant tachycardias have 1:1 AV relationship. The presence of AV block makes a reentrant tachycardia unlikely.

- b. *RP versus PR interval ratio*: The ratio of RP to PR helps in distinguishing various forms of supraventricular tachycardias. In typical AV nodal reentry, the atria and ventricles are activated simultaneously, thus the P waves are usually buried within the QRS complexes.

In patients with orthodromic tachycardias, which are mediated through accessory pathway the P wave can be seen outside the QRS complex and the RP interval is usually shorter than the PR interval (Fig. 3). In patients with atrial tachycardia the RP interval is generally longer than PR interval (Fig. 4).

Accessory pathway mediated tachycardia: The most frequently occurring arrhythmias in patients with pre-excitation are:

- a. Circus movement tachycardia.
- b. Atrial fibrillation

a. **Circus movement tachycardia:** A circus movement tachycardia with AV conduction over the AV node and retrograde conduction over the accessory pathway is called an **orthodromic tachycardia** (Figs 1C and 3). A tachycardia proceeding, in the reverse direction is an **antidromic tachycardia**.

Orthodromic tachycardia is much more frequent than an antidromic tachycardia. Antidromic tachycardia produces a broad QRS complex tachycardia. The QRS is wide and starts with a clear delta wave indicating initial ventricular activation outside the specific conduction system.

Some patients show no preexcitation during the sinus rhythm but have conduction only in the retrograde direction (concealed accessory pathways). These patients develop only orthodromic tachycardias. The concealed pathways may be having fast or slow retrograde conduction. The slowly conducting retrograde pathways are uncommon and generally cause paroxysmal junctional reentrant tachycardia, which may be incessant in children.

b. **Atrial fibrillation** (Fig. 5). The ventricles are usually protected by the refractory period of the AV node against a very rapid ventricular rate during a rapid atrial rhythm such as atrial fibrillation. In patients with accessory pathways, atrial fibrillation can be an extremely dangerous arrhythmia if the accessory pathway has a short antegrade refractory period. The ventricular rate is not only determined by the antegrade refractory period of an accessory pathway but also by the antegrade refractory period of the AV node.

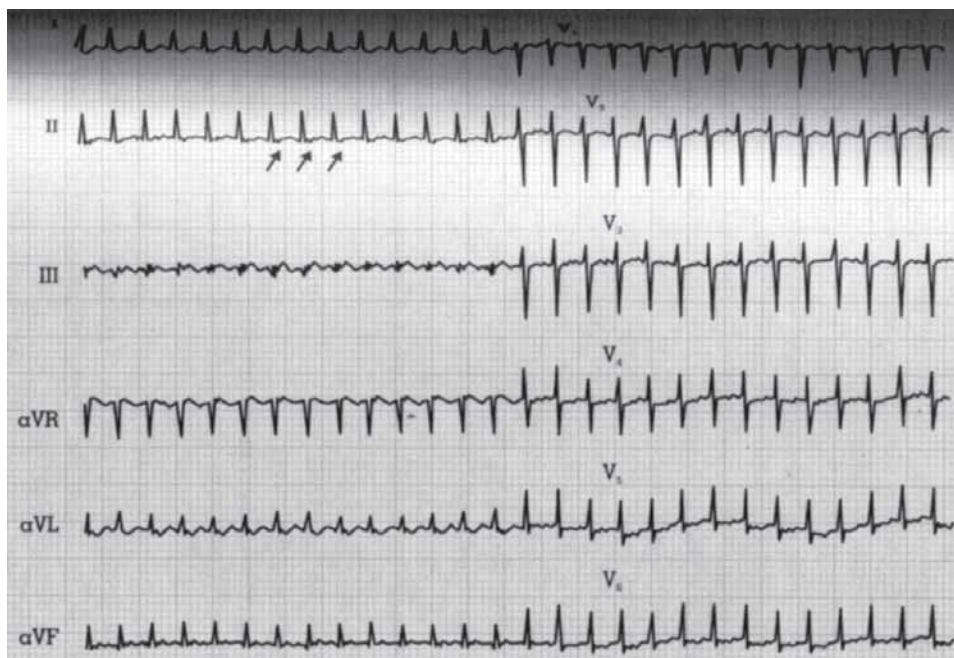


Fig. 3: A narrow QRS tachycardia, unlike Fig. 2 the P waves (inverted in leads II, III and aVF) are seen just outside the QRS complex, the RP interval is shorter than PR interval, this electrogram suggests an orthodromic tachycardia using an accessory pathway in the retrograde conduction

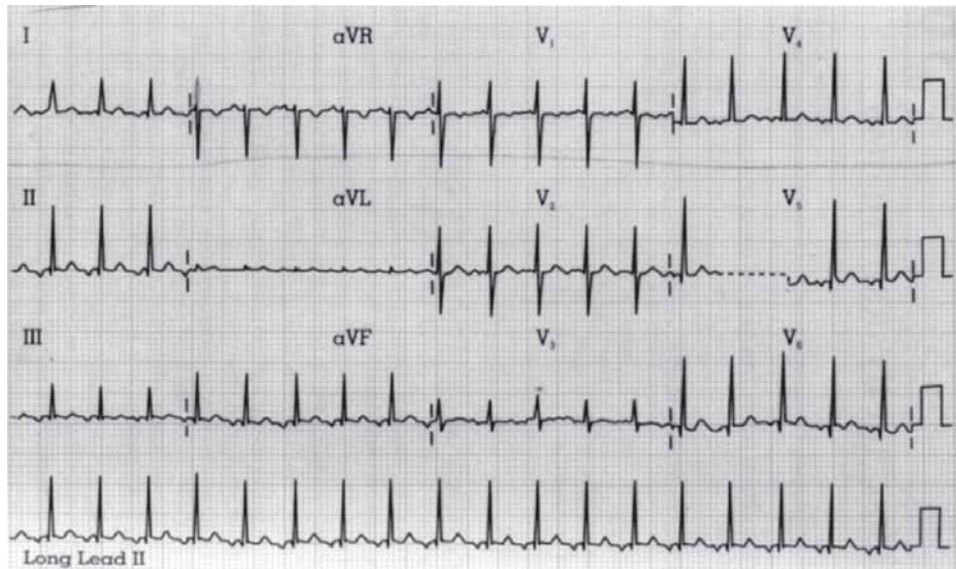


Fig. 4: A 19-year-old girl presented with recurrent palpitations, the 12 lead electrogram is consistent with the diagnosis of ectopic atrial tachycardia. The P waves are inverted in LII, LIII and aVF, the RP interval is longer than PR interval. This arrhythmia could not be controlled with drugs, the patient was successfully ablated from within the coronary sinus OS

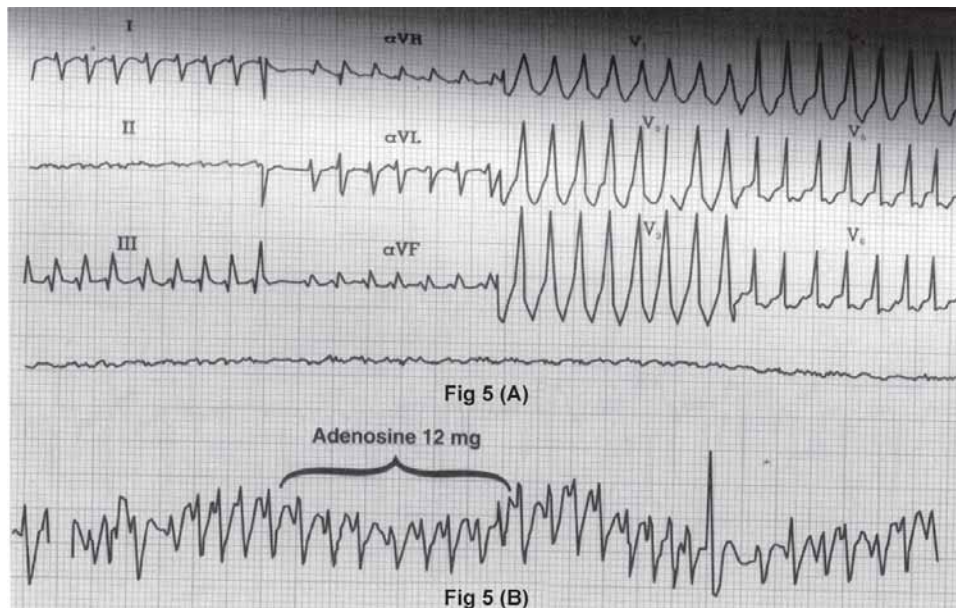


Fig. 5: A broad QRS irregularly irregular rhythm, the QRS complexes are of varying degree of duration, including some with a narrow QRS duration. This morphology is highly suggestive of atrial fibrillation with antegrade conduction over the accessory pathway. AV nodal blocking drugs can result in catastrophic outcome due to the entire conduction occurring over the accessory pathway leading to ventricular fibrillation, as is seen in figure 5 B where 12 mg adenosine converts this rhythm to ventricular fibrillation

Verapamil, betablockers or digoxin are contraindicated in patients with atrial fibrillation and antegrade conduction as by blocking the AV node they increase the conduction across the accessory pathway which may result at times in ventricular fibrillation.

Acute Treatment of SVTs Before discussing the choice of a drug, emphasis should be placed upon the effectiveness of vagal maneuvers (Table 3) that block the conduction in the AV node in the patient with circus movement tachycardia.

Table 3: Maneuvers used to interrupt a supraventricular tachycardia

- Carotid massage
- Valsalva maneuver
- Squatting (Valsalva)
- Gag reflex (finger in the throat)
- Dive reflex (immersion of face in cold water)

These should be performed as quickly as possible after the onset of tachycardia. The longer the delay, higher the sympathetic tone and less the possibility of a vagal maneuver being successful.

If vagal maneuvers are unsuccessful, the intravenous injection of a drug that prolongs the refractory period of the AV node (verapamil, diltiazem, adenosine, propranolol or amiodarone) or produce the lengthening of the refractory period of the accessory pathway (ajmaline, procainamide or amiodarone) usually terminates the circus movement tachycardia.

As with vagal maneuvers, treatment with intravenous adenosine has both diagnostic and therapeutic value. Data from randomized trials show that supraventricular tachycardia is terminated in 60 to 80% of patients treated with 6 mg of adenosine and in 90 to 95% of those treated with 12 mg. In patients with atrial tachycardias, adenosine causes a transient atrioventricular nodal block or interrupts the tachycardia. ECG monitoring is required during the administration of adenosine, and resuscitation equipment should be available in the event that the rare complications of bronchospasm or ventricular fibrillation occur.

If supraventricular tachycardia is refractory to adenosine or rapidly recurs, clinical experience indicates that the tachycardia can be terminated by the administration of intravenous verapamil or a beta-blocker.

The treatment of choice for patients with atrial fibrillation and preexcitation is influenced by the ventricular rate and hemodynamic consequences of the arrhythmia. Cardioversion should be done immediately if a rapid ventricular rhythm during AF leads to severe circulatory impairment. If the patient is hemodynamically stable, procainamide, ajmaline, amiodarone can be given intravenously (Table 4).

Table 4: Treatment of supraventricular tachycardia**AVNRT**

- a. Vagal maneuvers
- b. Diltiazem 0.25 mg/kg IV
- c. Adenosine (12-20 mg) IV
- d. Amiodarone (150-300 mg IV bolus)
- e. Verapamil 10 mg IV over 3 minutes
- f. Ajmaline 1 mg/kg IV
- g. Procainamide 10 mg/kg IV

Orthodromic tachycardia (same as above)

Antidromic tachycardia (AVRT)

- a. Procainamide 10 mg/kg
- b. Amiodarone (300 mg IV over 10-15 minutes)
- c. Ajmaline (1 mg/kg IV)

Atrial Fibrillation with WPW Syndrome

Hemodynamically not well tolerated - DC shock

Hemodynamically tolerated:

- Procainamide IV
- Ajmaline IV
- Disopyramide IV

After the acute management, most patients can now be offered a cure with a radiofrequency ablation particularly those with WPW syndrome. The success rates are high (95-98%) with low complications, making this a procedure of choice in these patients.

Atrial tachycardia. The atrial rate is generally 150 to 200 beats/minute and the P wave contour is different from that of sinus P wave. As the atrial rate increases the degree of AV block increases and Wenckebach second-degree block may ensue, i.e. atrial tachycardia with block.

EKG diagnosis (Fig. 4). Atrial tachycardia can sometimes become incessant particularly in children and young adults when over a prolonged period of time can lead to LV dysfunction and heart failure, this has termed as tachycardiomyopathy. This condition is reversible following the cure of the tachycardia, the LV function generally improved over a period of time.

Diagnosis

It has been demonstrated that there are two types of atrial flutter viz., (a) Type I or classic atrial flutter and (b) Type II or very rapid flutter.

Type I atrial flutter has an atrial rate of about 240-340bpm and can be interrupted by rapid atrial pacing. (Figs 6,7). Type II atrial flutter has an atrial rate ranging

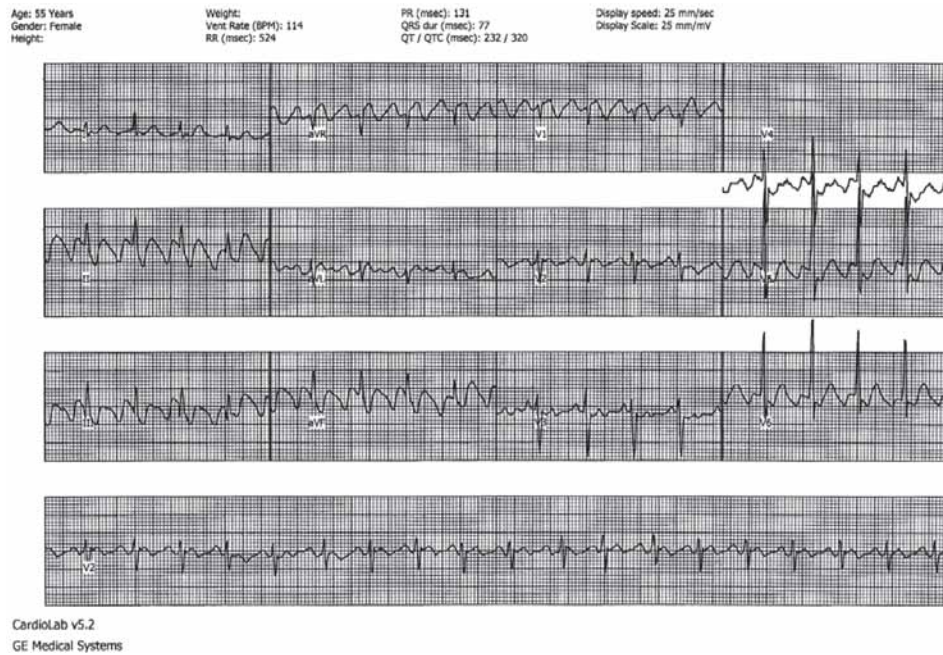


Fig. 6: Atrial Flutter with 2:1 AV block at atrial rate of 260 bpm and a ventricular rate of nearly 130 bpm. Note the saw tooth appearance of the P waves suggestive of atrial flutter

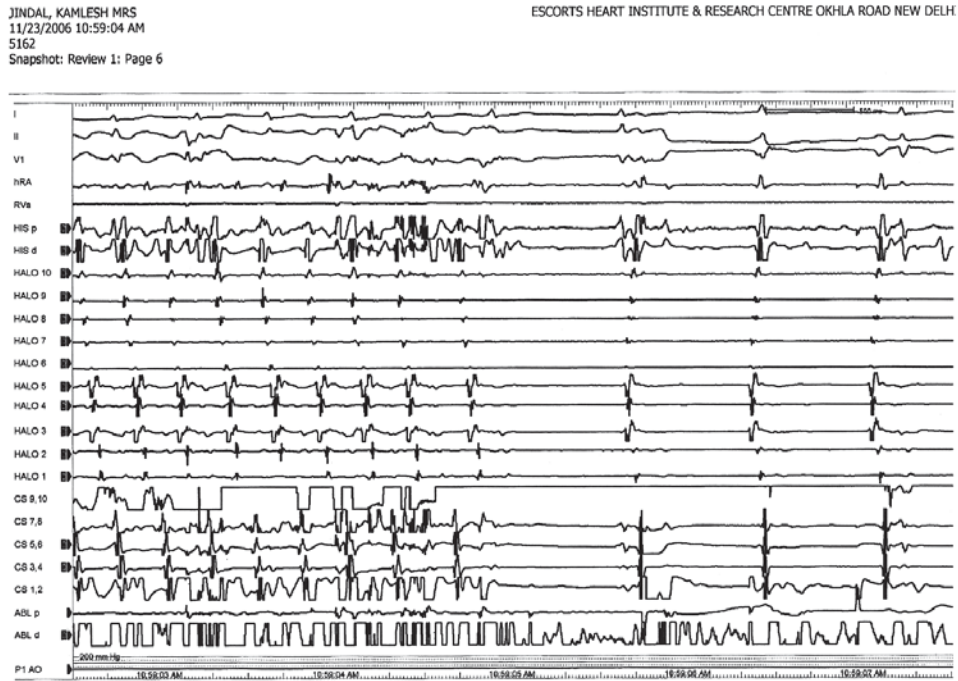


Fig. 7: Termination of atrial flutter during application of radiofrequency energy

from 340-440bpm and it cannot be interrupted by rapid atrial pacing. The appearance of the saw toothed flutter waves in the EKG particularly in leads II, III and aVF remains the standard for the diagnosis of atrial flutter

and is probably the easiest way to establish the diagnosis. If the heart rate is fast, carotid sinus massage may be used to produce transient AV block and allow the better analysis of the flutter waves. If the diagnosis

remains unclear, the following maneuvers may be used.

- a. Use of pharmacological agent—such as edrophonium, adenosine or esmolol, to increase AV conduction transiently
- b. Placement of an esophageal lead or an atrial lead for recording the atrial activity.

In the presence of WPW syndrome with possibility of atrial flutter, the use of pharmacological agents, which block the AV nodal conduction, is fraught with danger.

Treatment. When the diagnosis of atrial flutter is made three therapeutic options are available, viz.,

- a. Antiarrhythmic drug therapy
- b. DC current cardioversion
- c. Rapid atrial pacing to interrupt atrial flutter.

DC cardioversion or pacing is the preferred option. Drugs are less effective than these techniques. The indications for the use of drugs in this condition are:

- a. To slow the ventricular response rate (with either a betablocker or calcium channel blocker)
- b. To enhance the efficacy of rapid atrial pacing in restoring sinus rhythm (use of quinidine, procainamide or sotalol)
- c. To enhance the likelihood that the sinus rhythm will be sustained following effective DC cardioversion.

Selection of acute therapy for atrial flutter with either DC cardioversion or atrial pacing will depend on the clinical presentation of the patient and both the clinical availability and ease of applying either of these techniques. DC cardioversion has a very high likelihood of success. It requires as low as 25 J, however, since 100 J is virtually always successful and never harmful it should be considered as the initial shock.

Atrial fibrillation. The mechanisms involved in atrial fibrillation indicate that it results from multiple and concurrently circulating reentrant excitation wave fronts of the leading circle type in the atria. The electrocardiogram remains the gold standard for the diagnosis of atrial fibrillation. Classically, the EKG shows the absence of discrete atrial activity, a variable RR interval and an irregular baseline between QRS complexes. Occasionally this rhythm may be difficult to diagnose from the EKG. The coarse atrial fibrillation may mimic atrial flutter.

Treatment. Once the diagnosis of atrial fibrillation is established, two courses of therapy are available: (a) attempt to convert the rhythm to sinus rhythm using

DC cardioversion or antiarrhythmic drug therapy; (b) control the ventricular response rate using drugs such as digoxin, betablocker or a calcium channel blocker.

The choice between these approaches depends on the clinical status of the patients. As a general rule if the clinical situation is of hypotension or pulmonary edema, where prompt restoration to sinus rhythm is essential, DC cardioversion is the treatment of choice. If electric cardioversion is to be performed then it should be done after the administration of a type 1A agent or amiodarone to help maintain sinus rhythm after cardioversion. DC cardioversion establishes normal sinus rhythm in over 90% of patients, but sinus rhythm remains for 12 months in only 30-50%. Class IA, IC and III (amiodarone, sotalol) agents can be used to terminate acute onset atrial fibrillation and prevent recurrences of atrial fibrillation. Amiodarone appears to be superior to class IA agents based on the side effect profile and risk of proarrhythmia. These drugs increase the likelihood of maintaining sinus rhythm from about 30-50 to 50-70% per year after cardioversion.

POLYMORPHIC VT

Marked prolongation of the QT interval can be associated with the development of a polymorphic ventricular tachycardia known as torsade de pointes. This arrhythmia is caused by a specific electrophysiologic abnormality, triggered automaticity, that arises as a result of marked prolongation of the cardiac action potential. It is estimated that 1 to 8% of patients receiving quinidine will have torsade de pointes; hypokalemia and bradyarrhythmias are risk factors, and the arrhythmia is frequently “idiosyncratic,” occurring at low dosages and low plasma drug concentrations. Sotalol, an antiarrhythmic drug that prolongs the QT interval, is also associated with torsade de pointes. This drug is widely used in Europe and Canada and became available in the United States in early 1993. The incidence of torsade de pointes varies as a function of the dose of sotalol and may exceed 5% in patients receiving doses of 320 mg or more twice daily. Other antiarrhythmic agents that prolong the QT interval, including disopyramide, procainamide, and amiodarone, have also been associated with torsade de pointes. The incidence appears quite low with amiodarone, despite the marked prolongation of the QT interval it sometimes causes. Although most episodes of torsade de pointes are self-limited or associated with symptoms such as syncope, they can progress to ventricular fibrillation; the incidence of such progression is not known. Most recognized cases of torsade de pointes occur within days after the offending drug is initiated and, in patients being

treated for atrial fibrillation, after the restoration of normal sinus rhythm. However, some patients have torsade de pointes during long-term therapy, raising the possibility that fatal episodes contribute to an increase in mortality during therapy with some antiarrhythmic drugs. Polymorphic VT can also occur without QT prolongation, under these circumstances the commonest cause is severe ischemia resulting from obstructive coronary artery disease. The management here is treating ischemia with medications or revascularization, and there is no role anti-arrhythmics drugs except betablockers.

Summary

- The major groups of cardiac tachyarrhythmias are supraventricular and ventricular. The supraventricular tachyarrhythmias commonly seen are atrial tachycardia, supraventricular tachycardias, atrial flutter and atrial fibrillation.
- The common mechanisms of supraventricular tachycardias involve reentry using the AV node or reentry using a bypass tract, both producing a narrow QRS complex tachycardia. Acute management of these remains the same.
- For the acute management of supraventricular tachycardias, adenosine is the drug of choice, intravenous verapamil, diltiazem or beta-blockers are also useful. Radiofrequency ablation has emerged as a modality of choice for the long-term management of these patients.
- Ventricular tachycardia (VT) is the commonest cause of a broad QRS tachycardia. The differential diagnosis of a broad QRS tachycardia in the emergency room is crucial for the proper management of these patients. Sustained monomorphic and polymorphic VT represents two distinct entities. Polymorphic VT is usually seen in patients with an underlying heart disease, (coronary artery disease being the commonest) or with QT with QT prolongation.
- The acute treatment of VT depends on the hemodynamic stability of the patient, DC cardioversion is the method of choice for those with hemodynamic compromise. Intravenous antiarrhythmic drugs (xylocaine, procainamide, amiodarone, sotalol) may be tried for those who are hemodynamically stable. Oral amiodarone is the agent most commonly used for long-term management.