

Ventricular Tachycardia: Diagnosis of Broad QRS Complex Tachycardia

HEIN JJ WELLENS

INTRODUCTION

When confronted with a tachycardia having a broad QRS complex, it is important to be able to differentiate between a supraventricular and a ventricular tachycardia. Medication given for the treatment of a supraventricular tachycardia (SVT) may be harmful to a patient with a ventricular tachycardia (VT)^{1,2}. A reasonable hemodynamic condition during a tachycardia may erroneously lead to the wrong diagnosis of SVT³. Familiarity with the ECG signs allowing the diagnosis of a VT is therefore essential. But as will be discussed here, the ECG should not only tell you how to distinguish VT from other tachycardias with a broad QRS complex, but also to suspect its etiology and its site of origin in the ventricle. Both aspects are important in decision making about the prognostic significance of VT and correct treatment.

Classification of Tachycardias with a Broad QRS Complex

As shown in Figure 1, broad QRS tachycardia can be divided in three groups. SVT with bundle branch block (BBB) may be pre-existing or can occur when the refractory period of one of the bundle branches is reached because of the heart rate of the SVT (so called tachycardia related or phase 3 block). BBB can also occur because of retrograde invasion in one of the bundle branches⁴. These causes of BBB can be found in patients with atrial tachycardia, atrial flutter, atrial fibrillation, atrioventricular (AV) nodal tachycardia, and also during orthodromic circus movement tachycardia (with AV conduction over the AV node and ventriculo-atrial (VA) conduction over an accessory AV pathway).

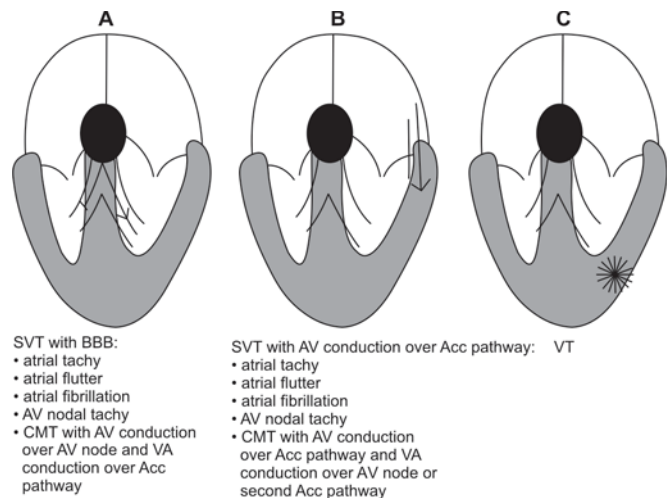


Fig. 1: Different types of SVT with BBB (diagram A), SVT with AV conduction over an accessory pathway (diagram B), and VT (diagram C) resulting in a broad QRS tachycardia.

Acc, accessory; AV, atrioventricular; BBB, bundle branch block; CMT, circus movement tachycardia; SVT, supraventricular tachycardia; VA, ventriculo-atrial; VT, ventricular tachycardia

SVT with AV conduction over an accessory AV pathway. This may occur during atrial tachycardia, atrial flutter, atrial fibrillation, AV nodal tachycardia, and during antidromic circus movement tachycardia (with AV conduction over an accessory AV pathway and VA conduction over the AV node or a second accessory AV pathway). It is also the case in the so called Mahaim tachycardia where AV conduction goes by way of a slowly conducting right sided accessory AV pathway or a nodo-ventricular fiber inserting into the right ventricle.

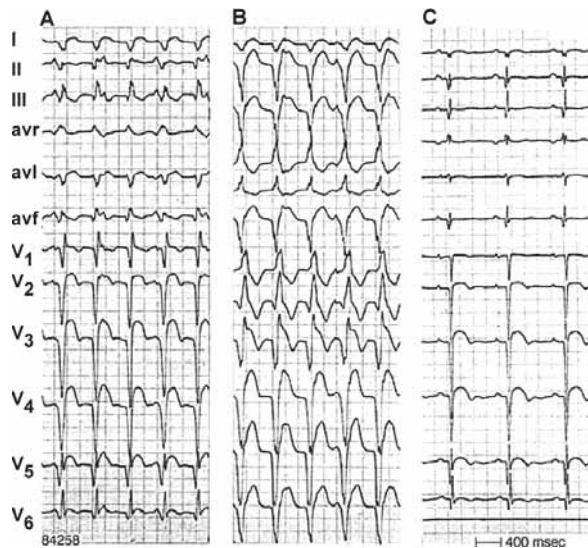


Fig. 2: Two types of VT (panel A and B) in the same patient (panel C during sinus rhythm). Atrioventricular dissociation is present during both VTs. Note the effect of the frontal plane axis on the R:S ratio in lead V6 in shaped VT. R:S < 1 is present in case of a superior axis (panel B), but R:S > 1 with an inferior axis (panel A)

Ventricular Tachycardia

Although dissociation between atrial and ventricular activity during tachycardia is a hallmark of VT (Fig. 2), some form of VA conduction can be present during VT, especially at slow VT rates⁴. P waves can be difficult to recognise during a broad QRS tachycardia and it is always useful to look for non-electrocardiographic signs such as variations in jugular pulsations, the loudness of the first heart sound, and changes in systolic blood pressure⁵.

In patients with slow VT rates occasional conduction from atrium to ventricle over the AV node-bundle branch system may happen resulting in “capture” or “fusion” beats. Sudden narrowing of a QRS complex during VT may also be the result of a premature ventricular depolarization arising in the ventricle in which the tachycardia originates, or it may occur when retrograde conduction during VT produces a ventricular echo beat leading to fusion with the VT QRS complex⁵. Very rarely, AV dissociation is present in tachycardias other than VT. It may occur in AV junctional tachycardia with BBB after cardiac surgery or during digitalis intoxication.

Width of the QRS Complex

As depicted in Figure 3, the site of origin of the VT plays a role in the width of the QRS complex. When the arrhythmia arises in the lateral free wall of the ventricle

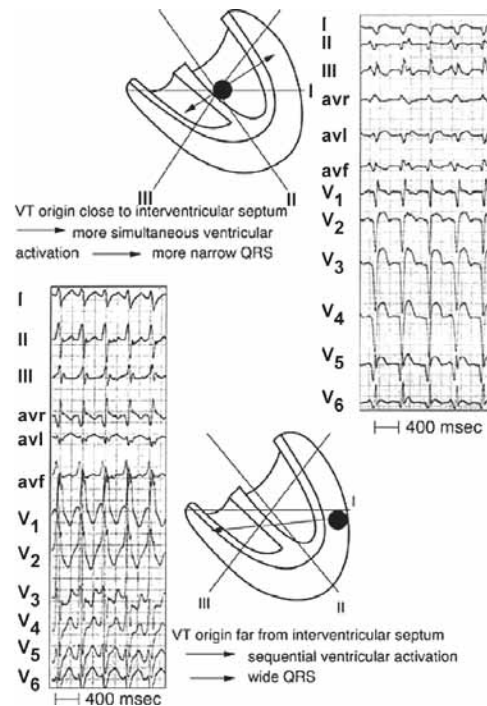


Fig. 3: VT origin and QRS width. Upper panel: an origin close to the interventricular septum results in more simultaneous right and left ventricular activation and therefore a more narrow QRS complex. In contrast (low panel) a VT origin in the lateral ventricular wall results in sequential ventricular activation and a wider QRS complex

sequential activation of the ventricles occurs resulting in a very wide QRS. The QRS complex will be smaller when the VT has its origin in or close to the interventricular septum. Of course other factors also play a role in the QRS width during VT, such as scar tissue (after myocardial infarction), ventricular hypertrophy, and muscular disarray (as in hypertrophic cardiomyopathy). It is of interest that a QRS width of more than 0.14 seconds in right BBB (RBBB) tachycardias and 0.16 seconds during left BBB (LBBB) argues for a VT⁴. But a QRS width below such values may occur in VTs having their origin in or close to the interventricular septum. Of course, QRS width is not helpful in differentiating VT from a tachycardia with AV conduction over an accessory AV pathway because such a pathway inserts into the ventricle leading to eccentric ventricular activation and a wide QRS complex.

An SVT can have a QRS width of more than 0.14 (RBBB) or 0.16 (LBBB) seconds under three circumstances:

- i. In the presence of pre-existent BBB in the elderly with fibrosis in the bundle branch system and ventricular myocardium;

- ii. When during SVT AV conduction occurs over an accessory AV pathway;
- iii. When class IC drugs (especially flecainide) are present during SVT.

QRS Axis in the Frontal Plane

The QRS axis is not only important for the differentiation of the broad QRS tachycardia but also to identify its site of origin and etiology. VT origin in the apical part of the ventricle has a superior axis (to the left of 30). An inferior axis is present when the VT has an origin in the basal area of the ventricle. Previous work⁴ showed that the presence of a superior axis in patients with RBBB shaped QRS very strongly suggests VT. This does not hold for an LBBB shaped tachycardia. On the contrary, presence of an inferior axis in LBBB shaped QRS tachycardia argues for a VT arising in the outflow tract of the right ventricle.

Configurational Characteristics of the QRS Complex

Leads V1 and V6: Marriott⁶ described that in RBBB shaped tachycardia, presence of a qR or R complex in lead V1 strongly argued for a ventricular origin of the tachycardia, while a three phasic (RSR) pattern suggested a supraventricular origin. Apart from lead V1, lead V6 can also be very helpful in correctly differentiating RBBB shaped tachycardia. When in V6 the R:S ratio is < 1 , a VT is very likely⁴. As shown in Figure 2B an R:S ratio < 1 in V6 is typically found when there is left axis deviation in the frontal plane. If the axis is inferiorly directed, lead V6 often shows an R:S ratio > 1 (Figure 2A). In LBBB shaped VT, lead V1 (and also V2) shows: an initially positive QRS with positivity measuring more than 0:03 seconds; slurring or notching of the downstroke of the S wave; and an interval between the beginning of the QRS and the nadir of the S wave of 0.07 seconds or more⁷. When lead V6 shows a qR pattern during LBBB shaped tachycardia, VT is very likely. In SVT with LBBB, lead V1 shows no or minimal initial positivity, a very rapid downstroke of the S wave, and a short interval between the beginning of the QRS and the nadir of the S wave (Fig. 4).

Interval Onset QRS to Nadir of S Wave in Precordial Leads

Brugada and colleagues⁸ suggested that an RS interval > 100 ms in one or more precordial leads is highly suggestive for VT. One should be careful, however, because such a duration may occur in SVT with

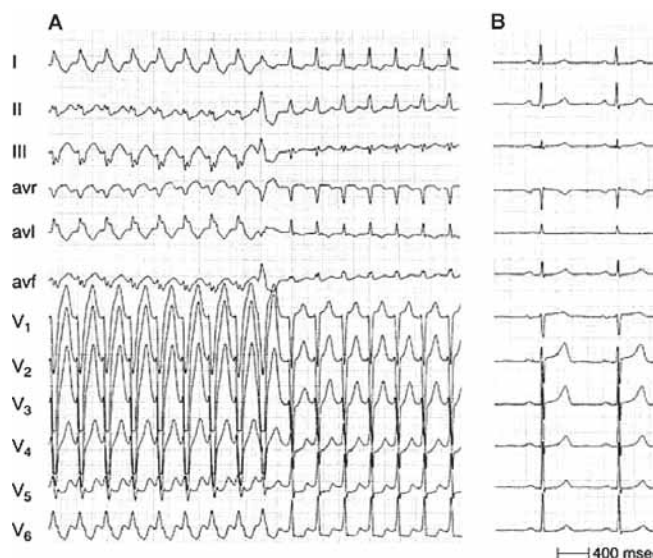


Fig. 4: SVT with LBBB. In panel A LBBB changes during tachycardia into a narrow QRS following a ventricular premature beat. As described in the text, lead V1 during LBBB clearly shows signs pointing to a supraventricular origin of the tachycardia

AV conduction over an accessory pathway, SVT during administration of drugs that slow intraventricular conduction (in particular, flecainide), and in SVT with pre-existent BBB, especially LBBB.

Concordant Pattern

When all precordial leads show either negative or positive QRS complexes this is called negative or positive concordancy. Negative concordancy is diagnostic for a VT arising in the apical area of the heart. Positive concordancy means that in the horizontal plane ventricular activation starts left posteriorly. This can be found either in VT originating in the left posterior wall or during tachycardias using a left posterior accessory AV pathway for AV conduction.

Tachycardia QRS More Narrow than Sinus QRS

When during tachycardia the QRS is more narrow than during sinus rhythm a VT should be diagnosed. A very wide QRS is present during sinus rhythm because of sequential activation of first the right and then the left ventricle. During tachycardia the QRS is more narrow. This can only be explained by a ventricular origin close to the intraventricular septum, resulting in more simultaneous activation of the right and left ventricle than during sinus rhythm.

Presence of QR Complexes

Coumel and colleagues⁹ called attention to the significance of a QR (but not a QS) complex during a broad QRS tachycardia, showing that their presence indicates a scar in the myocardium usually caused by myocardial infarction. QR complexes during VT are present in approximately 40% of VTs after myocardial infarction¹⁰.

Etiology of VT

Most VTs have a previous myocardial infarction as their etiology and, as pointed out, a QR complex during VT can be very helpful to make that diagnosis. However, characteristic ECG patterns can also be found in idiopathic VT¹¹ and VT in patients with arrhythmogenic right ventricular dysplasia (ARVD)¹². Figure 5 shows three patterns of idiopathic VT arising in or close to the outflow tract of the right ventricle. All three have an LBBB-like QRS complex indicating a right ventricular origin. In panel A the frontal QRS axis is +70 and lead 1 shows a positive QRS complex, indicating an origin of the tachycardia in the lateral part of the outflow tract of the right ventricle. In panel B the frontal QRS axis is inferior and the QRS is negative in lead 1, pointing to

an origin on the septal side in the right ventricular outflow tract. In panel C an inferior frontal QRS axis and QRS negativity in lead 1 are also present, but leads V1 and V2 clearly show initial positivity of the QRS complex. This is a tachycardia not arising on the endocardial surface of the right ventricular outflow tract but epicardially in between the root of the aorta and the posterior part of the outflow tract of the right ventricle. It is important to recognise this pattern because this site of origin of the VT cannot be treated with catheter ablation in contrast to the tachycardias depicted in panel A and B.

The QRS configuration in idiopathic left VT is shown in Figure 6. They all have an RBBB shape because of an origin in the left ventricle. The most common type is shown in panel A. The frontal QRS axis shows left axis deviation. The site of origin of the VT is in or close to the posterior fascicle of the LBB. In panel B the frontal QRS axis is further leftward (a so called north-west axis). This tachycardia arises more anteriorly close to the interventricular septum. The least common idiopathic left VT is the one shown in panel C. Now the frontal QRS axis is inferiorly directed. This VT originates in the anterior fascicle of the LBB. That area is difficult to reach by retrograde left ventricular catheterization and when

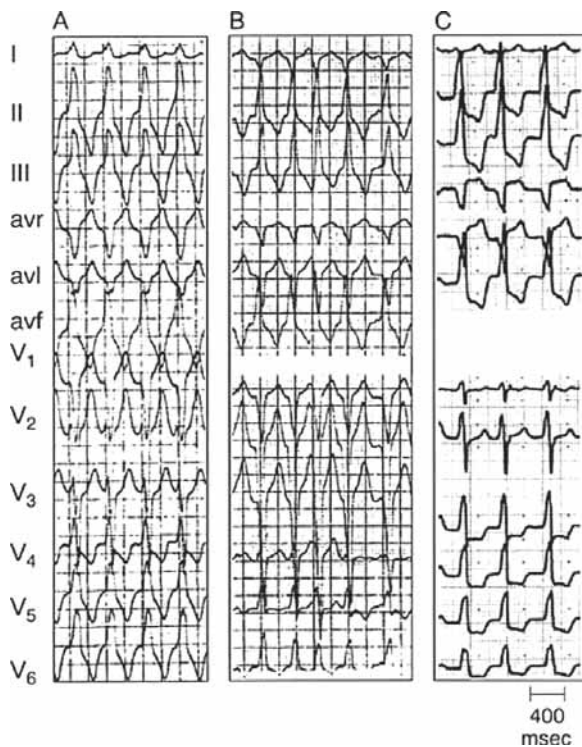


Fig. 5: Three types of idiopathic VT arising in or close to the outflow tract of the right ventricle (see text)

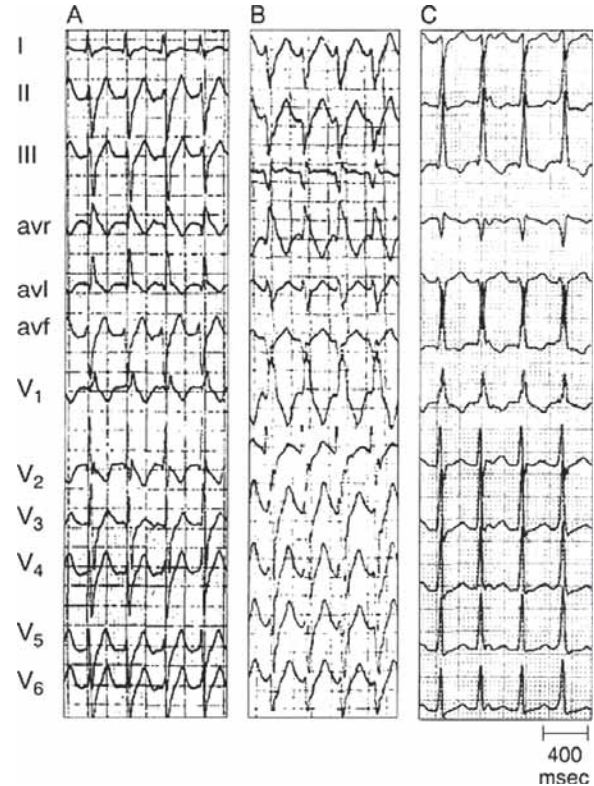


Fig. 6: Three types of left ventricular idiopathic VT (see text)

catheter ablation is considered an (atrial) transeptal catheterization should be favored. In ARVD there are three predilection sites in the right ventricle: the inflow and outflow tracts, and the apex. While the first two sites have a QRS configuration during tachycardia which is difficult to differentiate from right ventricular idiopathic VT, left axis deviation in a young person with an LBBB shaped VT should immediately lead to the suspicion of ARVD. In fact, there is an important rule in LBBB shaped VT with left axis deviation that cardiac disease should be suspected and that idiopathic right ventricular VT is extremely unlikely.

When the broad QRS is identical during tachycardia and sinus rhythm, one has to differentiate SVT with pre-existent BBB from bundle branch re-entrant tachycardia. In diseased hearts, especially when the bundle branches and the interventricular septum are involved, a tachycardia may occur based upon a circuit with anterograde conduction down one bundle branch or one of the left sided fascicles and after septal activation retrograde conduction over another branch of the bundle branch system (Fig. 7).

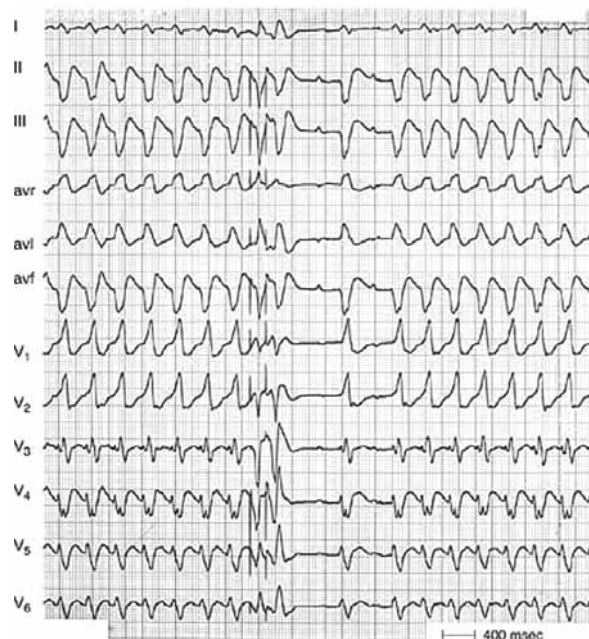


Fig. 7: Bundle branch re-entry VT. Following two electrically induced premature beats the tachycardia terminates in the middle of the recording. However, tachycardia resumes after two conducted sinus beats. The QRS is identical during sinus rhythm and tachycardia. Note the presence of AV dissociation during tachycardia indicating a ventricular origin.

This type of re-entry may occur in patients with antero-septal myocardial infarction, idiopathic dilated cardiomyopathy, myotonic dystrophy, after aortic valve surgery, and after severe frontal chest trauma

Value of the ECG During Sinus Rhythm

The ECG during sinus rhythm may show changes such as pre-existent BBB, ventricular pre-excitation, or an old myocardial infarction which are very helpful in correctly interpreting the ECG during broad QRS tachycardia. Also the presence of AV conduction disturbances during sinus rhythm make it very unlikely that a broad QRS tachycardia in that patient has a supraventricular origin and, a QRS width during tachycardia being more narrow than that during sinus rhythm points to a VT.

Value and Limitations of ECG Findings in Diagnosing Broad QRS Tachycardia

AV dissociation suggests VT, but VA conduction may be present during VT.

A QRS width of > 160 ms suggests VT, but need to rule out:

- Pre-existent BBB (especially LBBB)
- SVT with AV conduction over an AP
- Use of drugs slowing intraventricular conduction (flecainide).

Keep in mind VT arising close to or in the intraventricular conduction system may have a width of < 140 ms

Left axis deviation (to the left of 30°) suggests VT, but is not helpful in:

- LBBB shaped QRS
- SVT with conduction over a right sided or posteroseptal AP.
- SVT during use of class 1 C drugs

Right axis deviation (to the right of +90°) suggests VT in LBBB shaped QRS

Concordant pattern in precordial leads suggests VT, but positive concordancy may occur during SVT with AV conduction over a left posterior AP

R nadir S > 100 ms in one or more precordial leads suggests VT, but may be found in:

- SVT on drugs slowing intraventricular conduction
- SVT with AV conduction over an AP
- Pre-existent BBB (especially LBBB).

QR complexes during VT suggest previous myocardial infarction as etiology.

AP, accessory pathway; AV, atrioventricular; BBB, bundle branch block; LBBB, left bundle branch block; SVT, supraventricular tachycardia; VA, ventriculo-atrial; VT, ventricular tachycardia.

CONCLUSION

Do not panic when confronted with a broad QRS tachycardia. Look for clinical signs of AV dissociation and evaluate the 12 lead ECG systematically. Also, when available, look at the 12 lead ECG during sinus rhythm. This approach usually gives the correct diagnosis of VT versus SVT. Keep in mind that statistically VT is much more common than SVT in the broad QRS tachycardia. Never make the mistake of rejecting VT because the broad QRS tachycardia is hemodynamically well tolerated. When in doubt, do not give verapamil or adenosine; procainamide should be used instead.

REFERENCES

1. Stewart RB, Bardy GH, Greene HL. Wide complex tachycardia: Misdiagnosis and outcome after emergent therapy. *Ann Intern Med* 1986;104:766-71[Medline].
2. Buxton AE, Marchlinski FE, Doherty JU. Hazards of intravenous verapamil for sustained ventricular tachycardia. *Am J Cardiol* 1987;59:1107-10[Medline].
3. Dancy M, Camm AJ, Ward D. Misdiagnosis of chronic recurrent ventricular tachycardia. *Lancet* 1985;ii:320-323[Medline]. Three articles (refs 1-3) illustrating the dangers of giving calcium antagonists to patients with a broad QRS tachycardia erroneously interpreting a reasonable haemodynamic condition as pointing to an SVT.
4. Wellens HJJ, Bar FWHM, Lie KI. The value of the electrocardiogram in the differential diagnosis of a tachycardia with a widened QRS complex. *Am J Med* 1978;64:27-33[Medline]. First article systematically evaluating ECG findings in broad QRS tachycardia indicating value and limitations of AV dissociation, QRS width, QRS axis, and QRS characteristics in leads V1 and V6 to differentiate between VT and SVT.
5. Harvey WP, Ronan JA. Bedside diagnosis of arrhythmias. *Prog Cardiovasc Dis* 1966;8:419-445[Medline]. Physical examination is still of great value in the correct diagnosis of the patient with a tachycardia.
6. Marriott HJL. Differential diagnosis of supraventricular and ventricular tachycardia. *Geriatrics* 1970;25:91-101. The first systematic approach to use the ECG for differentiating tachycardias.
7. Kindwall E, Brown J, Josephson ME. Electrocardiographic criteria for ventricular tachycardia in wide QRS complex left bundle-branch block morphology tachycardia. *Am J Cardiol* 1988;61:1279-1283[Medline]. Basic information for the correct interpretation of LBBB shaped tachycardias.
8. Brugada P, Brugada J, Mont L, et al. A new approach to the differential diagnosis of a regular tachycardia with a wide QRS complex. *Circulation* 1991;83:1649-59[Abstract]. A useful approach to the ECG diagnosis of the broad QRS tachycardia.
9. Coumel P, Leclercq JF, Attuel P, et al. The QRS morphology in postmyocardial infarction ventricular tachycardia: A study of 100 tracings compared with 70 cases of idiopathic ventricular tachycardia. *Eur Heart J* 1984;5:792-805[Medline]. Important article indicating that the ECG contains information about the aetiology of the broad QRS tachycardia.
10. Wellens HJJ. The electrocardiographic diagnosis of arrhythmias. In: Topol E, ed. *Textbook of cardiovascular medicine*. Philadelphia: Lippincott, Raven, 1998;1591-609. This chapter includes an analysis of the incidence of QR complexes in a large series of patients with VT after myocardial infarction.
11. Wellens HJJ, Rodriguez LM, Smeets JL. Ventricular tachycardia in structurally normal hearts. In: Zipes DP, Jalife J, eds. *Cardiac electrophysiology from cell to bedside*, 2nd ed. Philadelphia: WB Saunders, 1995;780-8. A review of the ECG characteristics of patients with right and left sided idiopathic ventricular tachycardia.
12. Leclercq JF, Coumel PH. Characteristics, prognosis and treatment of the ventricular arrhythmias of right ventricular dysplasia. *Eur Heart J* 1989;10 (suppl D):61-70. ECG findings in patients with ARVD.