



Fibrinolytic Therapy in Complicated Parapneumonic Effusions and Empyema

MS Barthwal

Pulmonologist and Medical Specialist, Department of Respiratory Medicine,
Military Hospital (Cardio Thoracic Center), Pune-411040

114

ABSTRACT

Parapneumonic effusion is a common complication of pneumonia. Simple parapneumonic effusion, consisting of free flowing fluid, is usually managed with antibiotics alone. The complicated parapneumonic effusion and empyema are managed with tube drainage and antibiotics. The tube drainage in these types of effusions usually fails because of thick viscous fluid and pleural space loculations. The use of intrapleural fibrinolytic agents facilitates pleural space drainage and may obviate the need of more invasive surgical methods of pleural space drainage.

INTRODUCTION

Pneumonia remains one of the commonest community and hospital-acquired infection despite the advent of potent antimicrobial agents. As many as 36-57% of bacterial pneumonias develop parapneumonic effusion.^{1,2} The parapneumonic effusion may be "simple" consisting of free-flowing, clear exudative fluid which almost resolves completely with antibiotics alone. In case of delayed or inappropriate treatment some of these simple effusions progress to "complicated parapneumonic effusions" and "empyema". The management of these types of effusions with tube drainage and antibiotics fails most of the time due to thick viscous fluid and multiple pleural space loculations. This article comprises of an overview of management of complicated parapneumonic effusions and empyema and the current status of intrapleural fibrinolytic therapy especially in the Indian scenario.

PATHOPHYSIOLOGY OF PARAPNEUMONIC EFFUSION

To appreciate clinical utility of intrapleural fibrinolytic therapy it is important to understand the pathophysiology of parapneumonic effusion. Any pleural effusion associated with bacterial pneumonia lung abscess or bronchiectasis is a parapneumonic effusion.³ Empyema implies thick purulent-appearing pleural fluid. The progression of parapneumonic effusion can be divided into three stages. Although these stages are not so distinct, yet each can be diagnosed on the basis of some definite criteria. The first stage is an exudative stage which occurs during the first 48-72 hours and pleural fluid at this stage is free-flowing, non-turbid and sterile. The pleural fluid analysis shows pH>7.30, glucose>60mg/dl and LDH<500 U/L. In absence of appropriate therapy, the fibrinopurulent stage ensues. This stage is characterized by bacterial invasion resulting in accumulation

of large amount of pleural fluid with many polymorphonuclear leukocytes, bacteria and cellular debris. The pleural fluid becomes clottable due to leakage of plasma proteins and loss of fibrinolytic activity in pleural space resulting in the formation of thick layer of fibrin over parietal and visceral pleura. The migration of fibroblasts into pleural space leads to collagen deposition and along with dense layer of fibrin leads to formation of loculations. The pleural fluid at this stage is invariably turbid with pH<7.20, glucose level of <40mg/dl and LDH level of >1000 U/L. Most of the patients at this stage need pleural space drainage along with appropriate antibiotics to resolve the pleural sepsis. In case of delayed pleural space drainage and inappropriate antibiotics, the stage of empyema ensues over a period of two to several weeks. The empyema is either in the form of single loculus with thick inelastic pleural peel or it is multiloculated. The management of empyema is always by chest tube drainage with or without fibrinolytics or by surgical drainage.

CLASSIFICATION OF PARAPNEUMONIC EFFUSION: -

Though Light has classified parapneumonic effusion into seven categories,⁴ yet the more practical and easy to follow classification⁵ is as follows: -

1. Uncomplicated (Simple) Parapneumonic Effusion : This corresponds to exudative stage and pleural fluid is free-flowing, clear, sterile with pH>7.20, glucose>60mg/dl and LDH<1000 IU/L. It resolves with antibiotics alone.
2. Complicated Parapneumonic Effusion : This corresponds to late fibrinopurulent stage. The pleural fluid is usually clear or turbid but nonpurulent, usually has fibrin strands with or without loculations. The pH is <7.20, glucose<40mg% and LDH>1000 IU/L.
3. Empyema : Frank pus with single or multiple loculations.

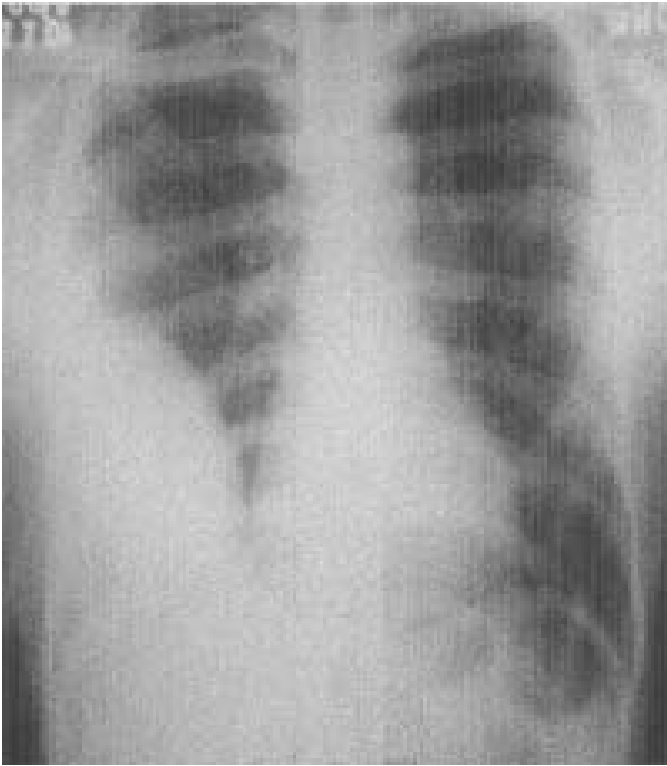


Fig. 1 : Chest radiograph PA view showing D-shaped opacity suggestive of loculated effusion.

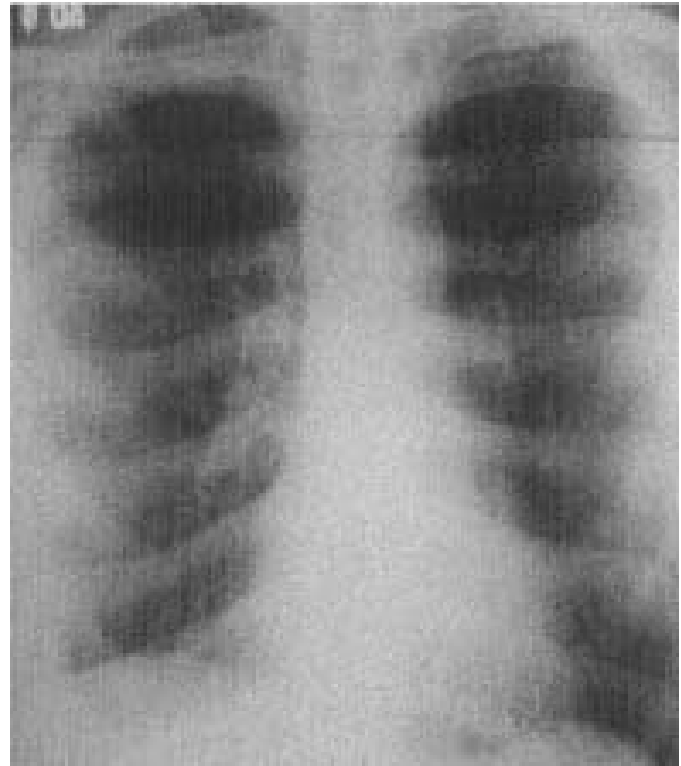


Fig. 2 : Chest radiograph PA view showing significant resolution of effusion after fibrinolytic therapy

DIAGNOSING PARAPNEUMONIC EFFUSIONS

The diagnosis of parapneumonic effusion is based on clinical, radiological and pleural fluid characteristics. The diagnosis of simple parapneumonic effusion and empyema is quite straightforward. The real challenge lies in diagnosing complicated parapneumonic effusion (CPE) at earliest so that timely pleural space drainage can be initiated. There are no definite clinical, radiological or biochemical parameters, which suggest CPE. However following parameters suggest the development of CPE.

Clinical⁶

- a. Prolonged symptoms prior to presentation.
- b. Combination of leukocytosis, anemia and hypoalbuminemia.
- c. Failure of clinical response to antibiotics.

Radiological

- a. Chest X-Ray PA, lateral and lateral decubitus views: The presence of D- shaped opacity or absence of typical sickle-shaped opacity (Fig.1), observed in free pleural fluid, is suggestive of CPE or empyema, which is loculated.
- b. Ultrasonography of Chest: It is a very useful and easily accessible test for detecting the presence of fibrin strands, septations or necrotic debris,⁷ the presence of which suggests the development of CPE.
- c. Computed tomography of Chest: It can reliably detect loculations, their number and sizes, and pleural thickening.

Pleural fluid characteristics

The fluid may be clear or cloudy/ turbid. In case of clear or slightly turbid fluid, pH can be measured using blood gas analyzer and heparinised sample. The biochemical analysis apart from routinely done protein estimation must include sugar and LDH estimate. The presence of pH<7.20, glucose<40 mg/dl and LDH>1000 IU suggest the diagnosis of CPE.⁵ The positive Gram stain or culture further confirms CPE. If pH testing is not possible because of inaccessibility to blood gas analyzer or turbid fluid, then finding of low glucose and high LDH along with presence of fibrin strands/septations in USG chest practically confirms the presence of CPE and is an indication for tube drainage.

INTRAPLEURAL FIBRINOLYTIC THERAPY

As discussed earlier, the standard management of CPE and empyema consist of antibiotics and pleural space drainage by standard chest tubes or small bore radiologically guided catheters. When the chest tube is adequately/ correctly positioned as evidence by chest radiography (PA and lateral views), ultrasound or CT scan, the major reasons for failed drainage are tube obstruction by thick, viscous fluid and multiple pleural space loculations.⁸ The various modalities of treatment available at this stage are saline flushes, placing one or more catheters in loculi under image guidance, thoracoscopic debridement and standard thoracotomy with empyectomy and decortications. The first two modalities are not so effective in improving drainage. The last two surgical modalities are more invasive, not easily available and if available are not affordable by majority of patients especially in a developing country like ours. The fibrinolytic agents, if used early in the fibrinopurulent stage within 4-6 wks of appearance

of effusion decrease viscosity, break loculations, dissolve thick debris and early fibrous peel, thus resolving the pleural sepsis and avoiding major surgical intervention (Fig 2). Tillet and Sherry⁹ first used the fibrinolytic agents in 1949 in 23 patients who had either loculated empyema or haemothorax. Their patients received intrapleural instillation of both STK and streptococcal desoxyribonucleases, which resulted in pleural fluid fibrinolysis and proteolysis. There was improvement in drainage of fluid. Subsequent investigations in small number of patients also reported improvement in clinical outcome. However, the initial enthusiasm waned because of significant systemic adverse effects in the form of fever, leukocytosis and general malaise. These side effects were due to immunological reaction caused by impurities in the preparation of agents. There was not much of use of this therapy until Bergh and colleagues¹⁰ in 1977 used purified streptokinase and reported significant improvement in 10 of 12 patients with empyema without the need for any major surgical intervention and without any significant adverse effects.

In the last twenty five years there have been numerous case series and randomized controlled trials using STK and urokinase (UK) in complicated parapneumonic effusion and empyema with encouraging results. There are about 25 uncontrolled case series¹¹ using intrapleural fibrinolytics (STK/UK). The number of patients in these case series varied from 3-30 and the indication for initiating fibrinolytic therapy was failed chest tube drainage in presence of patent and adequately positioned tube/catheter. STK dose used was 2,50,000 iu in 50-100 ml of saline daily and the tube was clamped for 2 – 4 hrs. The dosage of urokinase used in these studies has been in the range of 50,000- 1,00,000 iu. Number of instillations used were 2-10. Success criteria were increased volume of fluid drainage and clinical and radiological resolution of CPE / empyema. Success rate was 67-100% in these studies. The majority (>90%) of patients had no complications and 5-10% had transient fever, pleuritic chest pain and chest wall erythema. Both STK and UK were found to be equally effective but UK has the advantage of being non-antigenic.

Till date, there are four randomized trials of intrapleural fibrinolytic agents. In the first trial,¹² three doses of intrapleural STK was compared with saline flushes in 24 patient (13 with empyema and 11 with CPE). The STK group had significantly greater drainage of pleural fluid and radiological resolution. The second study¹³ compared urokinase and a saline placebo in 31 patients with pleural infection resulting in significantly more fluid drainage in urokinase group. In the third study,¹⁴ intrapleural STK was compared with only chest tube drainage in 52 patients (40 with empyema and 12 with CPE). A significantly larger volume of pleural fluid drained in STK group. All these studies, however, may be criticized for using the pleural fluid drainage and radiological improvement as primary outcome measures since it has been shown that radiological improvement does not reliably predict outcome¹⁵ and streptokinase can increase pleural fluid drainage due to mechanism independent of fibrinolysis.¹⁶ These problems were addressed in a recent randomized control trial¹⁷ in which forty-four patients were randomized to receive either STK or normal saline. The primary outcome measures in contrast to previous trials were taken as need for surgery, response to treatment and mortality, which as per the authors is the best way to scientifically approach a complex clinical problem

such as empyema. The significant beneficial effect of STK was seen between fourth and seventh day after initiation of treatment and there was reduced need for surgical referral in STK group. During last five years or so, the intrapleural streptokinase has been used with encouraging results in our country as reflected in various case reports,^{18,19} non-randomised trial²⁰ and a randomized trial.²¹

These uncontrolled case series and randomized controlled trials, in spite of low number of patients and non-uniform selection criteria, have nevertheless established the usefulness of fibrinolytic therapy with either STK or UK as an adjunctive therapy for CPE and empyema without any significant adverse effects. In a recent meta-analysis of randomized controlled trials,²² the usefulness of fibrinolytic therapy has been brought out but the therapy has not been recommended as a routine use due to small number of patients. A recently concluded Multicentre Intrapleural Streptokinase Trial (MIST trial), which randomized 450 patients with CPE and empyema from 72 British centers, to receive either twice daily STK or placebo for three days. Its results are awaited. It is also important to note that early initiation of fibrinolytic therapy, before the development of severe pleural adhesions, may lead to more effective drainage as has been demonstrated in experimental²³ and clinical studies.²⁴

However, there has been a problem in adopting daily schedule of intrapleural STK/UK in our country due to non-availability of required dosage of STK/UK. The minimum strength of STK freely available in our country is 7,50,000 iu/ vial and once the vial is reconstituted the solution can be stored only for 8 hours at 2-8° C. We have been using intrapleural STK in the dosage of 2,50,000 iu 8 hourly. This way we could at least utilize two doses, thereby minimizing the wastage of this costly drug and at the same time maintaining its potency. The same dosing regimen was used in cases reported earlier from this country^{18,19} and in a recently published study.²⁰ The same problem exists with urokinase with the minimum availability of 2.5000 iu/vial as the minimum strength. We have been using it in the dosage of 100,000 iu 8 hourly for similar reasons as for STK. We had to resort to this increased dosage out of compulsion. However, Strange et al¹⁶ in an experimental study demonstrated that increasing dosing interval might in fact increase the efficacy of fibrinolytic therapy. The possible explanation for this is that due to various protease inhibitors in the inflamed pleural space the half-life and, therefore, the proteolytic activity of STK is shortened and increasing dosing frequency can prolong the same. How much contribution to the successful outcome of this therapy can be attributed to increase dosing frequency needs to be further evaluated by a controlled trial. The intrapleural fibrinolytic therapy has also been used successfully in pediatric patients as reflected by various case reports^{26, 27} and a randomized control trial.²⁸

Adverse effects of fibrinolytic agents

Fever, chest pain has been reported in <10% of patients. Major hemorrhage was reported in a single case report after 5,00,000 iu of STK and dwell time of 6 hrs.²⁹ There have been isolated case reports of ventricular fibrillation following urokinase.³⁰ It is recommended not to exceed single dose of >2,50,000 of STK or 100,000 of UK and dwell time more than four hours. Some

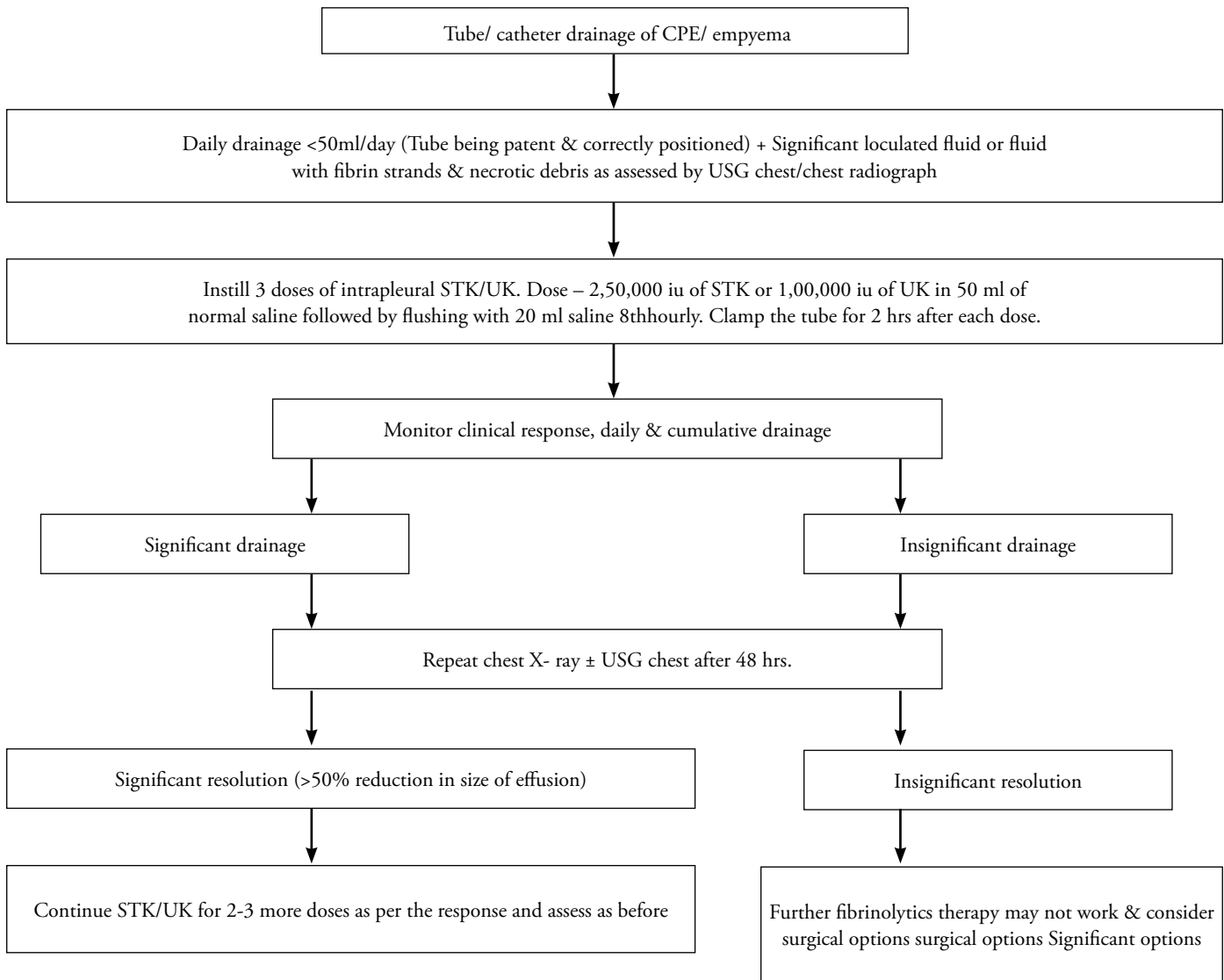


Fig. 3 : Suggested protocol for intrapleural fibrinolytic therapy

studies have recommended the use of antihistaminics and steroids before fibrinolytics. There is no significant activation of systemic fibrinolytic system even with a total dose of 1.5 miu given in a dose of 2,50,000 iu 12 hourly and no monitoring of coagulation parameters is required.²⁵

Contraindications of using fibrinolytic therapy

H/O bleeding diathesis, stroke, significant hemorrhage in the preceding six months, bronchopleural fistula and use of STK by any route in the previous two years.

There has been no standardized protocol as yet for fibrinolytics therapy. However, following is the suggested protocol (Figure 3).

FUTURE PROSPECTS

It has been hypothesized that purulent exudates contain almost equal proportion of fibrin and deoxyribose nucleoprotein and both STK and streptodornase are necessary for the liquefaction of fibrin and deoxyribose nucleoprotein.³¹ The recent two

in vitro studies^{31,32} have shown increased liquefaction and decreased viscosity of empyema fluid and pus by using STK with streptodornase. New human recombinant DNase is available and its use along with STK/UK may give much better results and completely avoid any surgical interventions.

CONCLUSION

The intrapleural fibrinolytic therapy is a useful adjunctive therapy in the management of CPE and empyema without any significant side effects. However, more randomised controlled trials are required for establishing definite treatment protocols.

REFERENCES

1. Light RW, Girad WM, Jenkinson SG, et al. Parapneumonic effusion. *Am J Med* 1980; 69:507-12.
2. Taryle DA, Potts DE, Sahn SA. The incidence and clinical correlates in parapneumonic effusion in pneumococcal pneumonia. *Chest* 1978;74: 170-3.
3. Light RW, MacGregor MI, Ball WC Jr, et al. Diagnostic significance of pleural fluid pH and PCO₂. *Chest* 1973; 64:591-596.

4. Light RW. Pleural diseases. IVth ed. Philadelphia: Lippincott Williams and Wilkins.2001; 165-66.
5. Davies CWH, Gleeson FV, Davies RJO. BTS guidelines for the management of pleural infection. *Thorax* 2003;58(Suppl II): ii18-ii28.
6. Alfageme I, Munoz F, Pena N, et al. Empyema of the thorax in adults. Etiology, microbiological findings and management. *Chest* 1993;103: 839-43.
7. McCloud TC, Flower CDR. Imaging the pleura: sonography, CT and MR imaging. *AJR* 1991;156:1145-53.
8. Boland GM, Lee MJ, Silverman S, et al. Interventional radiology of the pleural space. *Clin Radiol* 1995; 50:205-214.
9. Sherry S, Johnson A, Tillett WS. The action of streptococcal deoxyribose nuclease (streptodornase) in vitro, and on purulent pleural exudations of patients. *J Clin Invest* 1949; 28: 1094-1104.
10. Bergh NP, Ekroth R, Larsson S, Nagy P. Intrapleural streptokinase in the treatment of hemothorax and empyema. *Scand J Thorac Cardiovasc Surg* 1977;11:265-268.
11. Sahn SA. Use of fibrinolytic agents in the management of complicated parapneumonic effusions and empyema. *Thorax* 1998; 53 (Suppl 2) S:656-572.
12. Davies RJO, Traill ZC, Gleeson FV. Randomised controlled trial of intrapleural streptokinase in community acquired pleural infections. *Thorax* 1997; 52: 416-421.
13. Bouros D, Schiza S, Tzanakis N, et al. Intrapleural urokinase versus normal saline in the treatment of complicated parapneumonic effusions and empyema. A randomized double blind study. *Am J Respir Crit Care Med* 1999; 159: 37-42.
14. Chin NK, Lim TK. Controlled trial of intrapleural streptokinase in the treatment of pleural empyema and complicated parapneumonic effusions. *Chest* 1997; 111:275-279.
15. Davies W, Kearney S, Gleeson F, Davies R. Predictors of outcome and long-term survival in patients with pleural infection. *Am J Respir Crit Care Med* 2003;160:1682-1686.
16. Strange C, Allen ML, Harley R, et al. Intrapleural streptokinase in experimental empyema. *Am Rev Respir Disease* 1993; 147: 962-6.
17. Diacon A H, Theron J, Schuurmans M M, Bernard W, Wal V, Bolliger C T. Intrapleural streptokinase for empyema and complicated parapneumonic effusions. *Am J Respir Crit Care Med* 2004;170:49-53.
18. Sharma VP, Guleria R, Gupta R, Sharma SK, Pandey JN. Intrapleural streptokinase in multiloculated empyema thoracis. *J Assoc Physicians India* 1998; 46:227-29.
19. Barthwal MS. Intrapleural streptokinase in complicated parapneumonic effusion. *J Assoc Physician India* 1998; 46: 907-8.
20. Barthwal MS, Deoskar R B, Rajan K E, Chatterjee R S. Intrapleural streptokinase in complicated parapneumonic effusions and empyema. *Indian J Chest Dis Allied Sci* 2004; 46:7-11.
21. Talib SH, Verma GR, Arshad M, Tayade BO, Rafeeqe A. Utility of intrapleural streptokinase in management of chronic empyemas. *J Assoc Physicians India* 2003; 51:464-468.
22. Cochrane Review. Intrapleural fibrinolytic therapy versus conservative management in the treatment of parapneumonic effusions and empyema. Cochrane Library, Issue 3, 2004. John Wiley and sons, Chichester, UK.
23. Strange C, Baumann MH, Sahn SA, Idell S. Effects of intrapleural heparin or urokinase on the extant of tetracycline induced pleural disease. *Am J Respir Crit Care Med* 1995; 151:158-15.
24. Bouros D, Schiza S, Tzanakis N, et al. Intrapleural urokinase versus normal saline in the treatment of complicated parapneumonic effusions and empyema. A randomized double blind study. *Am J Respir Crit Care Med* 1999; 159: 35-42.
25. Davies CWH, Lok S, Davies RJO. The systemic fibrinolytic activity of intrapleural streptokinase. *Am J Respir Crit Care Med* 1998; 157: 328-30.
26. Rosen H, Nadkarni V, Theroux M, Padman R, Klein J. Intrapleural Streptokinase as adjunctive treatment for persistent empyema in paediatric patients. *Chest* 1993;103:1190-93.
27. Barthwal MS. Intrapleural streptokinase in a two-year-old child with parapneumonic effusion. *Indian J Chest Disease Allied Sci* 2001;43: 165-168.
28. Thomson A H, Hull J, Kumar R, et al. A Randomised trial of intrapleural urokinase in the treatment of childhood empyema. *Thorax* 2002;57: 343-47.
29. Godley PJ, Boll RC. Major haemorrhage following administration of intrapleural streptokinase. *Chest* 1984;86:486-7.
30. Alfagame I, Vazquez R. Ventricular fibrillation after intrapleural urokinase. *Intensive Care Med* 1997; 23: 352.
31. Light R W, Nguyen T, Mulligan M E, Sasse S A. The in vitro efficacy of varidase versus streptokinase or urokinase for liquefying thick purulent exudative material from loculated empyema. *Lung* 2000;1278:13-18.
32. Simpson G, Roomes D, ChB M B, Heron M. Effects of streptokinase and deoxyribonuclease on viscosity of human surgical and empyema pus. *Chest* 2000;117:1728-33.