

# CARDIOLOGY

---

- 1. A previously well 27 year old woman presents with a history of transient ischaemic attack affecting her right side and speech. On examination there was nothing abnormal to find. An ECG, chest Xray, CT brain scan and routine haematology and biochemistry were all normal. What is the most likely underlying abnormality?**

  - atrial myxoma
  - carotid artery stenosis
  - embolus from paroxysmal atrial fibrillation
  - patent foramen ovale
  - subarachnoid haemorrhage
- 2. A 51 year old woman has had several syncopal episodes over the past year. Each episode is characterized by sudden but brief loss of consciousness. She has no chest pain. She has no ankle edema. On brain MRI there is a 1.5 cm cystic area in the left parietal cortex. A chest Xray shows no cardiac enlargement, and her lung fields are normal. Her serum total cholesterol is 6.5 mmol/L. Which of the following cardiac lesions is she most likely to have?**

  - Cardiac amyloidosis
  - Ischemic cardiomyopathy
  - Left atrial myxoma
  - Mitral valve prolapse
  - Tuberculous pericarditis
- 3. A 66 year old man has developed chronic renal failure with a serum urea of 60 mmol/L and creatinine of 650 micromol/L. Auscultation of the chest reveals a friction rub over the cardiac apex. He is most likely to have a pericarditis that is termed?**

  - Constrictive
  - Fibrinous
  - Hemorrhagic
  - Purulent
  - Serous
- 4. Which ONE of the following is a contraindication to thrombolysis?**

  - age over 75 years
  - the presence of atrial fibrillation
  - asthma
  - pregnancy
  - background diabetic retinopathy
- 5. Which of the following antimicrobials is associated with prolongation of the QT interval?**

  - Coamoxiclav
  - Gentamicin
  - Cefuroxime
  - Erythromycin
  - Isoniazid
- 6. A 60 year old man presents with an inferior MI and receives thrombolysis. 4 hours following initial presentation he becomes acutely breathless. His ECG demonstrates sinus tachycardia (rate 108 bpm) with T wave inversion inferiorly. His ST segments are normal. On examination his JVP is elevated at 5 cm. Chest was clear to auscultation. Following 80 mg of Frusemide he deteriorates. His BP is now 80/60 and his urine output over the last 2 hours is 5 ml. What is the best investigative measure over the last 2 hours?**

  - Arterial Blood Gases
  - Central Venous Pressure Monitoring
  - Chest XRay
  - Echocardiography
  - Pulmonary Capillary Wedge Pressure Monitoring
- 7. Which of the following is a recognised feature of massive pulmonary embolism?**

  - reduced plasma lactate levels
  - an increase in serum troponin levels
  - an arterial pH less than 7.2
  - blood gases show increased pCO<sub>2</sub> on air
  - normal D-dimer levels
- 8. A 60 year old man has worsening congestive heart failure with increasing pulmonary oedema. His blood pressure is normal. He has been healthy all his life with no major illnesses. A serum glucose is 5.6 mmol/L. His total serum cholesterol is 4.8 mmol/L. The serum creatine kinase is not elevated. The most likely explanation for these findings is?**

  - Alcoholic cardiomyopathy
  - Aortic dissection
  - Calcified bicuspid aortic valve
  - Mitral valve annulus calcification
  - Tricuspid valve endocarditis
- 9. During auscultation of the heart you discover a wide fixed splitting of the second heart sound. In which of the following conditions does this occur?**

  - an uncomplicated ASD
  - Fallot's tetralogy
  - aortic stenosis
  - Right Bundle Branch Block
  - constrictive pericarditis
- 10. A 62 year old man has experienced substernal chest pain upon exertion with increasing frequency over the past 1 year. An electrocardiogram shows T wave inversion in the anterolateral leads at rest. He has a total serum cholesterol of 7.0 mmol/L. On angiography, he has an 85% narrowing of the left anterior descending artery. Which of the following events is most likely to occur in this patient?**

  - A systemic artery embolus from thrombosis in a peripheral vein.
  - A systemic artery embolus from a left atrial mural thrombus.
  - Pulmonary embolism from a left ventricular mural thrombus
  - A systemic artery embolus from a left ventricular mural thrombus.
  - Pulmonary embolism from thrombosis in a peripheral vein.
- 11. A 17 year old girl was found collapsed and drowsy. Her 12 lead ECG showed a sinus tachycardia of 120 beats per minute with a corrected QT interval of 500 ms (normal <470). Which of the following is the most likely cause of her presentation?**

  - Amphetamine
  - Diphenhydramine
  - Glue sniffing
  - Methadone
  - Methanol

12. A randomised double-blind placebo controlled study of a cholesterol lowering drug for the primary prevention of coronary heart disease was conducted. It had a five year follow up period. The results showed an absolute risk of myocardial infarction in the group receiving placebo during was 10 percent. The relative risk of those given the cholesterol lowering medication was 0.8. What number of patients will need to be treated with the drug for five years to prevent one myocardial infarction?
- 20
  - 40
  - 50
  - 80
  - 100
13. Which ONE of the following is true regarding acute pulmonary embolism?
- a normal ECG excludes the diagnosis
  - embolectomy is more effective than thrombolysis in improving survival
  - Heparin is as effective as thrombolytic therapy
  - the presence of hypoxaemia is an indication for thrombolysis
  - thrombolysis administered through a peripheral vein is as effective as through a pulmonary artery catheter
14. A 70 year old woman has a history of dyspnoea and palpitations for six months. An ECG at that time showed atrial fibrillation. She was given digoxin, diuretics and aspirin. She now presents with two short lived episodes of altered sensation in the left face, left arm and leg. There is poor coordination of the left hand. ECHO was normal as was a CT head scan. What is the most appropriate next step in management?
- anticoagulation
  - carotid endarterectomy
  - clopidogrel
  - corticosteroid treatment
  - no action
15. A 21 year old man with Hypertrophic Cardiomyopathy presents in clinic with dizzy spells but has not had any syncopal episodes. Which of the following, if present, would indicate an increased risk of sudden cardiac death?
- Asymmetric septal hypertrophy with maximum wall thickness of 2.1 cm
  - Blood Pressure drop of 20 mmHg during peak exercise tolerance testing
  - Left Ventricular Outflow Tract Gradient of 80 mmHg
  - Systolic Anterior Movement of the mitral valve on echocardiography
  - Worsening exertional angina
16. Whilst attending the cardiology clinic, the staff nurse measures the blood pressure of a 61 year old man, and finds that it is 183/100 mmHg sitting and 190/105 standing. He has a heart rate of 81/minute, with an irregularly irregular rhythm. On auscultation of the heart, there are no murmurs, but he has bibasilar crackles on chest examination. Which of the following pathological findings is most likely to be present?
- Left ventricular hypertrophy
  - Left atrial myxoma
  - Occlusive coronary atherosclerosis
  - Cor pulmonale
  - Mitral regurgitation
17. A 24 year old woman develops infective endocarditis involving the aortic valve. She receives a porcine bioprosthesis because of her desire to have children and not to take anticoagulant medication. After ten years, she must have this prosthetic valve replaced. Which of the following pathologic findings in the bioprosthesis has most likely led to the need for replacement?
- Calcification with stenosis
  - Dehiscence
  - Infective endocarditis
  - Strut failure
  - Thrombosis
18. A randomised, double-blind, placebo controlled trial of a cholesterol lowering drug in the primary prevention of coronary heart disease is reported. 1000 subjects are treated with the active drug, and 1000 are given placebo. They are followed up over a five year period and 100 individuals in the placebo group and 80 in the treatment group suffer a myocardial infarction. What is the annual percentage risk of myocardial infarction in the group treated with placebo?
- 0.5%
  - 2%
  - 5%
  - 8%
  - 10%
19. A 25 year old previously healthy woman has worsening fatigue with dyspnoea, palpitations, and fever over the past one week. Her vital signs on admission to the hospital show Temperature 38.9°C Respiratory rate 30/min Pulse 105 bpm and BP 95/65 mmHg. Her heart rate is irregular. An ECG shows diffuse ST segment changes. A Chest Xray shows mild cardiomegaly. An echocardiogram shows slight mitral and tricuspid regurgitation but no valvular vegetations. Her troponin I is 12 ng/mL. She recovers over the next two weeks with no apparent sequelae. Which of the following laboratory test findings best explains the underlying etiology for these events?
- ANCA titer of 1:80
  - Anti-streptolysin O titer of 1:512
  - Blood culture positive for Streptococcus, viridans group
  - Coxsackie B serologic titer of 1:160
  - Total serum cholesterol of 9.6 mmol/l
20. A 74 year old man presented with acute pain, pallor and absent pulses in his right leg. Investigations revealed an embolus in his femoral artery. What is the most likely source of this embolus?
- marantic endocarditis
  - paradoxical emboli
  - rheumatic endocardial vegetations
  - right ventricular thrombi
  - thrombi from an atheromatous aorta
21. Which of the following concerning congenital heart disease is correct?
- ASD is the commonest malformation at birth
  - congenital complete heart block is usually associated with Anti-Ro antibodies in the mother
  - Ebstein's anomaly is associated with maternal exposure to lithium carbonate
  - Hypoplastic left heart syndrome is characterised by a large, dilated left ventricle
  - Osteogenesis imperfecta is associated with aortic stenosis
22. Which of the following regarding the anatomy of the heart is true?
- The aortic valve is tricuspid.
  - The ascending aorta is entirely outside the pericardial sac.
  - The left atrial appendage is identified readily by transthoracic echocardiography.

- d. The pulmonary trunk lies anterior to the ascending aorta.  
e. The right atrium is posterior to the left atrium.
23. A patient presents with atrial fibrillation and later they revert to sinus rhythm. Under which of the following circumstances is the patient more likely to remain in sinus rhythm?  
a. age > 75 years old  
b. been commenced on warfarin  
c. left atrium size > 6 cm on ECHO  
d. short history of AF  
e. ventricular rate on presentation of 130 bpm
24. A 68 year old man has been very ill for months following the onset of chronic liver disease with hepatitis C infection. He experiences a sudden loss of consciousness and then exhibits paraplegia on the right. A cerebral angiogram reveals lack of perfusion in the left middle cerebral artery distribution. The most likely cardiac lesion to be associated with this finding is?  
a. Acute rheumatic fever  
b. Left atrial myxoma  
c. LibmanSacks endocarditis  
d. Nonbacterial thrombotic endocarditis  
e. Paradoxical thromboembolus
25. A 65 year old man presents with severe central crushing chest pain. ECG shows evidence of an inferior myocardial infarction. He receives TPA, Heparin and Aspirin. Four hours after initial presentation, he starts feeling dizzy and breathless. His pulse is 40 bpm regular, BP 80/50. Heart sounds are soft and chest clear to auscultation. ECG shows 2:1 AV block with T wave inversion inferiorly. IV atropine was administered but had no effect. What is the next most important treatment?  
a. IV Dopamine.  
b. IV Isoprenaline.  
c. Insert a permanent pacemaker.  
d. Insert a temporary pacemaker.  
e. Monitor his progress.
26. A 70 year old male is referred by his GP for management of recently diagnosed congestive heart failure. The patient has a history of poorly controlled hypertension. Over the last three months he has been aware of deteriorating shortness of breath, fatigue, and orthopnea. Over the last month he had been commenced on Digoxin (62.5 micrograms daily), Frusemide (80 mg daily), and amiloride 10 mg. On examination he has a pulse of 96 bpm regular, a blood pressure of 132/88 mmHg. His JVP was not raised, he had some scattered bibasal crackles on auscultation with a displaced apex beat in the anterior axillary line, 6th intercostal space. Auscultation of the heart revealed no murmurs and he had peripheral oedema to the mid tibia. Investigations showed: electrolytes normal serum urea concentration 17 mmol/l (NR 28 mmol/l) creatinine 175 micromol/l (NR 55-110). Serum digoxin 0.7 ng/mL (therapeutic: 1.02-0). One month previously his urea had been 11 mmol/l and creatinine 110 micromol/l. An ECG reveals left ventricular hypertrophy and Chest Xray shows cardiomegaly and calcified aorta. What is the most appropriate next step in management?  
a. Add an ACE inhibitor to the current regimen  
b. Add atenolol at a dose of 25mg daily  
c. Increase digoxin to 0.25 mg daily  
d. Increase frusemide to 80 mg twice daily  
e. Maintain on current therapy.
27. A 14 year old boy presents with hypertension. Which of the following statements concerning hypertension in the young is true?  
a. Sodium nitroprusside is useful for the long term treatment of severe cases.  
b. Headache is the usual presenting feature.  
c. It is defined as systolic blood pressure above the 99th centile for age.  
d. Abnormalities are frequently seen on DMSA scan.  
e. Aortic coarctation is the commonest secondary cause.
28. A 23 year old male presents with a deep vein thrombosis. He has no past medical history but his mother has suffered from deep vein thromboses. Which of the following is likely to be found on haematological assessment?  
a. Factor V Leiden mutation  
b. Protein S deficiency  
c. Protein C deficiency  
d. Antithrombin deficiency  
e. Lupus anticoagulant
29. In a normal heart, the oxygen saturation of a sample of blood taken from a catheter in the pulmonary capillary wedge position should be equal to a sample from which of the following?  
a. coronary sinus  
b. femoral artery  
c. pulmonary artery  
d. right atrium  
e. right ventricle
30. A 60 year old man with a past history of controlled hypertension presents with acute onset weakness of his left arm, that resolved over 12 hours. He had suffered two similar episodes over the last three months. Examination reveals a blood pressure of 132/82 mmHg and he is in atrial fibrillation with a ventricular rate of 85 per minute. CT brain scan is normal. What is the most appropriate management?  
a. amiodarone  
b. aspirin  
c. digoxin  
d. dipyridamole  
e. warfarin
31. In a patient presenting with aortic stenosis, which of the following findings would be most helpful in establishing a diagnosis of congenital bicuspid valve as the etiology?  
a. age  
b. calcified leaflets  
c. commissural fusion on ECHO  
d. negative history for rheumatic fever  
e. systolic ejection click
32. A 55 year old woman was found to have ++ glycosuria and had a maternal history of Type II diabetes mellitus. She was a smoker of 20 cigarettes per day. Examination reveals no specific abnormalities apart from a BMI of 30. Blood pressure was 132/88 mmHg. Investigations reveal: serum creatinine 80 µmol/L (60 - 110) plasma glucose (fasting) 11.3 mmol/L (3.0 - 6.0) total serum cholesterol 5.5 mmol/L (<5.2) HDL cholesterol 1.4 mmol/L (>1.55) What is most likely to improve her life expectancy?  
a. Metformin 500 mg bd  
b. Ramipril 10 mg daily  
c. Simvastatin 10 mg daily  
d. Stopping smoking  
e. Weight loss to achieve a BMI of 25
33. Which of the following concerning the use of intravenous bicarbonate in cardiorespiratory arrest is correct?  
a. exacerbates intracellular acidosis

- b. has a positive inotropic effect on ischaemic myocardium  
 c. improves oxygen release to the tissues  
 d. increases cerebral blood flow  
 e. reduces preexistent hyperkalemia
34. Primary prevention trials for the treatment of hypercholesterolaemia reveal a reduction in all cause mortality following treatment with which of the following?  
 a. Fibrates  
 b. Fish Oils  
 c. Nicotinic acid  
 d. Resins  
 e. Statins
35. A 30 year old man presents with a history of transient loss of consciousness and palpitations. His ECG shows ventricular tachycardia. Which of the following treatments should be avoided?  
 a. adenosine  
 b. amiodarone  
 c. DC cardioversion  
 d. flecainide  
 e. verapamil
36. A 56 year old male with left ventricular systolic dysfunction was dyspnoeic on climbing stairs but not at rest. The patient was commenced on ramipril and frusemide. Which one of the following drugs would improve the patient's prognosis?  
 a. Amiodarone  
 b. Amlodipine  
 c. Bisoprolol  
 d. Digoxin  
 e. Nitrate therapy
37. A 44 year old man has had no major medical problems throughout his life, except for arthritis pain involving all extremities for the past couple of years. He has had worsening orthopnoea and ankle oedema in the past six months. He is afebrile. There is no chest pain. A chest Xray shows cardiomegaly with both the past six months. He is afebrile. There is no chest pain. A chest Xray shows cardiomegaly with both enlarged left and right heart borders, along with pulmonary oedema. Laboratory test findings include sodium 139 mmol/L, potassium 4.3 mmol/L, urea 7 mmol/L, creatinine 95  $\mu$ mol/L, and glucose 8.6 mmol/L. Which of the following additional laboratory test findings is he most likely to have?  
 a. Anticentromere antibody titer of 1:320  
 b. Erythrocyte sedimentation rate of 79 mm/Hr  
 c. Haemoglobin of 10.7 g/dL with MCV of 72 fL  
 d. Serum ferritin of 3400 pmol/L  
 e. Spherocytes in his peripheral blood smear
38. Which of the following is a recognised feature of a beta lipoproteinaemia?  
 a. a high serum cholesterol  
 b. palmar xanthomas  
 c. advanced atherosclerotic vascular disease  
 d. abnormal red blood cell morphology  
 e. severe mental retardation
39. Which of the following infections is least likely to cause myocarditis?  
 a. Coxsackie virus  
 b. Diphtheria  
 c. Chagas Disease  
 d. Syphilis  
 e. Toxoplasmosis
40. A 68 year old woman was admitted to hospital with evidence of biventricular cardiac failure. On examination her pulse was 100 beats per minute (sinus rhythm), and her blood pressure was 140/60 mmHg. She had haemorrhages in both fundi. Her condition improved after intravenous diuretics. Investigations revealed: haemoglobin 5.6 g/dl (11.5 – 16.5) haematocrit 0.19 (0.36 – 0.47) MCV 118 fl (80 – 96) MCH 33.0 pg (28 – 32) WCC 3.4 x 10<sup>9</sup>/L (4 – 11) platelet count 95 x 10<sup>9</sup>/L (150 – 400) What is the next most appropriate step in management?  
 a. blood transfusion  
 b. bone marrow aspiration  
 c. intramuscular vitamin B12 alone  
 d. intramuscular vitamin B12 and oral folic acid together  
 e. oral folic acid alone
41. Which of the following compounds has a vasodilating effect?  
 a. Antidiuretic hormone  
 b. Calcitonin  
 c. Endothelin  
 d. Renin  
 e. Somatostatin
42. Which of the following may be responsible for a hypokalaemic hypertension?  
 a. Nonclassical congenital adrenal hyperplasia  
 b. Barter's syndrome  
 c. Diabetic nephropathy  
 d. Liddle's syndrome  
 e. Type IV renal tubular acidosis
43. A 52 year old sales representative is admitted with an inferior myocardial infarction. He receives thrombolysis and makes an uneventful recovery. He is discharged on atenolol, aspirin and orvastatin. He enquires how long after his MI must he wait before he is able to drive?  
 a. One week  
 b. Two weeks  
 c. Four weeks  
 d. Three months  
 e. Six months
44. A 35 year old woman presented with a history of intermittent lightheadedness. Clinical examination and 12 lead ECG were normal. Which of the following, if present on a 24 hour Holter ECG tracing, would be the most clinically important?  
 a. Atrial premature beats.  
 b. Profound sleep associated bradycardia.  
 c. Supraventricular tachycardia.  
 d. Transient Mobitz type 1 atrioventricular block.  
 e. Ventricular premature beats.
45. A 57 year old man develops deep venous thrombosis during a hospitalization for prostatectomy. He exhibits decreased mental status with right hemiplegia, and a CT scan of the head suggests an acute cerebral infarction in the distribution of the left middle cerebral artery. A chest Xray reveals cardiac enlargement and prominence of the main pulmonary arteries that suggests pulmonary hypertension. His serum troponin I is <0.4 ng/mL. Which of the following lesions is most likely to be present on echocardiography?  
 a. Coarctation of the aorta  
 b. Dextrocardia

- c. Pulmonary stenosis  
d. Tetralogy of Fallot  
e. Ventricular septal defect
46. A 60 year old man had a myocardial infarction 6 weeks ago. He is taking aspirin 75 mg/day and metoprolol 50 mg 2/day. During a routine followup Exercise Test he has a 20 beat run of nonsustained VT. He achieved stage 4 of the Bruce protocol and 92 % of his target heart rate. The nonsustained VT occurred halfway through Stage 2. ST segments were normal during the study. What is the definitive investigation?
- Coronary angiography.
  - Echocardiogram.
  - Electrophysiological study.
  - Thallium exercise scan.
  - 24 hour Holter monitor.
47. A 55 year old woman has had worsening shortness of breath for several years. She now has to sleep sitting up on two pillows. She has difficulty swallowing. There is no history of chest pain. She is afebrile. Recently, she suffered a stroke with left hemiparesis. A chest Xray reveals a near normal left ventricular size with a prominent left atrial border. Which of the following conditions is most likely to account for these findings?
- Aortic coarctation
  - Cardiomyopathy
  - Essential hypertension
  - Left renal artery stenosis
  - Mitral valve stenosis
48. Which of the following antiarrhythmic drugs may be used in the treatment of long QT syndrome?
- Amiodarone
  - Atenolol
  - Flecainide
  - Propofanone
  - Sotalol
49. A 70 year old male was receiving amiodarone 200 mg daily for intermittent atrial fibrillation. However, he was aware of tiredness and lethargy. He appeared clinically euthyroid with no palpable goitre. Investigations revealed: Serum free T4 23pmol/L (926) Serum total T3 0.8 nmol/L (0.92.8) Serum TSH 8.2 mU/L (<5) Which of the following statements would explain these results?
- Abnormal thyroxine binding globulin
  - Amiodarone induced hypothyroidism
  - 'sick euthyroid' syndrome
  - Spontaneous hypothyroidism
  - TSH secreting pituitary adenoma
50. A 65 year old woman, a heavy smoker for many years, has had worsening dyspnoea for the past 5 years, without a significant cough. A chest Xray shows increased lung size along with flattening of the diaphragms, consistent with emphysema. Over the next several years she develops worsening peripheral oedema. BP 115/70 mmHg. Which of the following cardiac findings is most likely to be present?
- Constrictive pericarditis
  - Left ventricular aneurysm
  - Mitral valve stenosis
  - Nonbacterial thrombotic endocarditis
  - Right ventricular hypertrophy
51. An elderly man with a history of asthma, congestive heart failure, and peptic ulcer disease is admitted with bronchospasm and rapid atrial fibrillation. He receives frequent nebulised salbutamol and IV digoxin loading, his regular medications are continued. 24 hours after admission his serum potassium is noted to be 2.8 mmol/L. Which of his medications is most likely to have caused this abnormality?
- Digoxin
  - ACE inhibitor
  - Salbutamol
  - Ranitidine
  - Spironolactone
52. In the diagnosis of rheumatic fever, which of the following may be helpful?
- A generalised macular papular rash.
  - ASO titre of less than 1:200.
  - Polyarthritis.
  - Staphylococcus aureus grown on throat culture.
  - Splinter haemorrhages.
53. A 55 year old man presents with gynaecomastia while receiving treatment for Heart failure. Which of the following drugs is most likely to be the cause of his gynaecomastia?
- Amiloride
  - Carvedilol
  - Furosemide
  - Omeprazole
  - Ramipril
54. A 78 year old female is referred by her GP with high blood pressure. Over the last three months her blood pressure is noted to be around 180/80 mmHg. She has a body mass index of 25.5 kg/m<sup>2</sup>, is a nonsmoker. There are no features to suggest a secondary cause for her hypertension. Which of the following is the most appropriate treatment for her blood pressure?
- Alpha Blocker
  - Angiotensin Converting Enzyme (ACE) Inhibitor
  - Angiotensin Blocker
  - Beta blocker
  - Calcium channel blocker
55. A 17 year old woman loses consciousness while out jogging one afternoon, as she has done for many years. She is taken to where a chest Xray, CT brain scan, FBC, and biochemistry are all normal. Over the next year, she develops mild dyspnoea and fatigue. There are several episodes of presyncope. After another syncopal episode, she is referred to a cardiologist who orders an ECG that shows changes of left ventricular hypertrophy and broad Q waves. An echocardiogram reveals left ventricular and septal hypertrophy, small left ventricle, and reduced septal excursion. The septum has a "ground glass" appearance. She then dies suddenly and unexpectedly. The microscopic appearance of the septum with trichrome stain reveals myofiber disarray. Which of the following conditions is she most likely to have had?
- Diabetes mellitus
  - Hypertrophic cardiomyopathy
  - Rheumatic heart disease
  - Systemic lupus erythematosus
  - Viral myocarditis
56. Which of the following is true regarding the coronary circulation?
- Adenosine is the most important mediator of metabolic vasodilation.

- b. Coronary blood flow is independent of myocardial oxygen consumption due to autoregulation.
- c. Coronary blood flow within a normal range of blood pressure is primarily determined by perfusion pressure.
- d. Increased myocardial O<sub>2</sub> demand is met primarily by increasing O<sub>2</sub> extraction.
- e. The vasodilatory reserve of the epicardium and endocardium is equivalent under normal physiologic conditions.
57. **A 54 year old man presents with central crushing chest pain. Examination is normal. 12 lead ECG shows STsegment elevation in leads II, III, aVF and ST depression in V1, V2 and V3. Which coronary artery is occluded?**
- Circumflex
  - Left Anterior Descending
  - Left Main Stem
  - Obtuse Marginal
  - Right Coronary Artery
58. **Which of the following is true regarding mitral stenosis?**
- it is tolerated well in pregnancy
  - there is characteristically a low wedge pressure
  - in AF, the opening snap disappears
  - The opening snap is not heard when the mitral valve is heavily calcified
  - Doppler U/S is usually inaccurate in determining severity
59. **A 26 year old man is noted to have cyanosis of the lower limbs and clubbing of the toes but not the fingers. Which of the following statements is true?**
- He has Eisenmenger's syndrome.
  - He has coarctation of the aorta.
  - He is likely to have a loud continuous 'machinery' murmur below the left clavicle.
  - He is likely to need urgent surgery.
  - He has had a Blalock shunt operation.
60. **A 74 year old man has had increasingly severe, throbbing headaches for several months, centered on the right. There is a palpable tender cordlike area over his right temple. His heart rate is regular with no murmurs, gallops, or rubs. Pulses are equal and full in all extremities, BP is 110/85 mmHg. A biopsy of this lesion is obtained, and histologic examination reveals a muscular artery with luminal narrowing and medial inflammation with lymphocytes, macrophages, and occasional giant cells. He improves with a course of high dose corticosteroid therapy. Which of the following laboratory test findings is most likely to be present with this disease?**
- Anti double stranded DNA titer of 1:1024
  - Erythrocyte sedimentation rate of 110 mm/hr
  - HDL cholesterol of 0.6 mmol/L
  - pANCA titer of 1:160
  - Rheumatoid factor titer of 80 IU/mL
61. **A 27 year old woman complained of palpitations, breathlessness and chest pain, radiating to the left arm. These symptoms had developed six weeks previously, after she had witnessed her father dying from a myocardial infarction. In the past 10 years she had been investigated for abdominal pain, headaches, joint pains, and dyspareunia, without serious cause being found for these symptoms. What is the most likely diagnosis?**
- Depressive episode
  - Factitious disorder
  - Generalized anxiety disorder
  - Hypochondriasis
  - Somatization disorder
62. **A 35 year old healthy woman has a faint systolic murmur on physical examination. An echocardiogram is performed, and she is found to have a bicuspid aortic valve. In explaining the meaning of this finding to her, the most appropriate statement is that?**
- An aortic valve prosthesis may eventually need to be placed
  - Other family members may have the same condition
  - She should be treated with a cholesterol lowering agent
  - The problem resulted from past injection drug usage
  - This is one manifestation of an underlying autoimmune disease process
63. **Which of the following findings is the most specific for a diagnosis of myocardial infarction?**
- anakinetic area of LV wall motion on ECHO
  - elevated cardiac enzymes
  - evolution of Q waves on ECG
  - history of severe chest pain
  - ST elevation on ECG
64. **A 15 year old female presents following a sore throat with chest pain, fever, and a skin rash. Examination reveals a diastolic murmur. Her ASO titre is elevated. Which of the following is a major criterion for the diagnosis of Rheumatic fever?**
- Fever
  - Raised ESR
  - Polyarthritis
  - Migratory erythema
  - Prolonged PR interval
65. **A 55 year old man with Type 2 Diabetes Mellitus and Ischaemic Heart Disease has been researching the Internet! He asks your opinion on Laser Transmyocardial Revascularisation. Which of the following statements about this technique is true?**
- avoids the need for major surgery
  - damages the endocardium
  - involves destruction of coronary stenoses
  - is of particular use in severe proximal coronary artery disease
  - stimulates collateral vessel formation
66. **On auscultation of the heart of a 30 year old female a loud first heart sound is heard. Which of the following may be responsible for this auscultatory feature?**
- a long preceding diastolic interval
  - Atrial premature beat
  - increased pulmonary arterial pressure
  - increased systemic arterial pressure
  - rupture of a papillary muscle
67. **A 64 year old man is admitted with a right femoral neck fracture following a fall. Also seen in the radiograph of the pelvis are several prominent calcified vessels. What is the most appropriate next step in management of this finding?**
- anticoagulate with heparin
  - Ignore it
  - Order a pulmonary ventilation/perfusion scan
  - Request a serum troponin test
  - Start the patient on a nitrate infusion
68. **A 59 year old man who was active all his life develops sudden severe anterior chest pain that radiates to his back. Within minutes, he is unconscious. He has a history of hypertension, but a recent treadmill test had revealed no evidence for cardiac disease. Which of the following is the most likely diagnosis?**

- a. Acute myocardial infarction  
b. Group A streptococcal infection  
c. Pulmonary embolus  
d. Right middle cerebral artery embolus  
e. Tear in the aortic intima
69. Which ONE of the following statements is true about the diastolic Austin Flint murmur?  
a. It is associated with a loud first heart sound.  
b. It is an early sign of aortic regurgitation  
c. It can be distinguished from the murmur of mitral stenosis by absence of presystolic accentuation  
d. It is due to partial closure of the anterior leaflet of the mitral valve  
e. It does not occur in aortic incompetence secondary to an aortitis
70. A 28 year old man who is known to have Hypertrophic Cardiomyopathy has an out of hospital cardiac arrest and is successfully resuscitated. What is the most appropriate mode of treatment?  
a. Alcohol Septal Ablation  
b. Amiodarone  
c. Beta Blocker  
d. Implantable Defibrillator  
e. Myomectomy
71. A 14 year old boy presents with fever. Which of the following might contribute to a diagnosis of rheumatic fever?  
a. The finding of target lesions on the hands.  
b. The finding of tender nodules in the fingertips.  
c. A prolonged PR interval on ECG.  
d. A CRP of 10.  
e. Positive Romberg's sign.
72. A 40 year old man attending a routine screening has a blood pressure of 166/100 mmHg. Two weeks later his blood pressure was 150/90 mmHg. He does not smoke. He drinks 35 units alcohol / week. His body mass index (BMI) is 30 kg/m<sup>2</sup> (20-25). What is the best management strategy?  
a. amlodipine  
b. atenolol  
c. bendrofluazide  
d. enalapril  
e. lifestyle advice
73. A 19 year old woman is found to have a cardiac murmur characterized by a midsystolic click. An echocardiogram reveals mitral insufficiency with upward displacement of one leaflet. There is also aortic root dilation to 4 cm. She has a dislocated right ocular crystalline lens. She dies suddenly and unexpectedly. The medical examiner finds a prolapsed mitral valve with elongation, thinning, and rupture of chordae tendinae. A mutation involving which of the following genes is most likely to be present in this patient?  
a. Beta myosin  
b. CFTR  
c. FGFR  
d. Fibrillin  
e. Spectrin
74. A 51 year old businessman complains of dyspnoea on exertion. He recently returned from a business trip to the USA. He has distant heart sounds on auscultation of the chest. A chest radiograph reveals that there is a thin rim of calcification surrounding the cardiac outline. Which of the following conditions is most likely responsible for these findings?  
a. Uraemia  
b. Tuberculosis  
c. Group B coxsackie virus  
d. Sarcoidosis  
e. Metastatic carcinoma
75. A 60 year old woman is admitted with sudden onset of chest pain and is diagnosed with an acute myocardial infarction. Her acute illness is complicated by low blood pressure and poor tissue perfusion for several days. Her serum lactate becomes elevated. Her serum urea and creatinine are noted to be increasing.
- Day 1 Day 2 Day 3  
urea (mmol/L) 8 22 30  
creatinine (µmol/L) 116 140 200
- Granular and hyaline casts are present on microscopic urinalysis. The renal lesion that is most likely to be present in this situation is?  
a. Acute tubular necrosis  
b. Minimal change disease  
c. Nodular glomerulosclerosis  
d. Pyelonephritis  
e. Renal vein thrombosis
76. A 45 year old male type 1 diabetic with a number of complex diabetic gastrointestinal complications is noted to have a PR interval of 0.18s, a QRS duration of 0.1s and a QT interval of 0.48s on routine ECG. Which of the following drugs may be responsible?  
a. Cisapride  
b. Octreotide  
c. Cotrimoxazole  
d. Domperidone  
e. Cimetidine
77. You are asked to see a patient in the Intensive Care Unit who is short of breath and tachycardic to rule out a cardiac cause of her symptoms. A right heart catheter reveals that the mixed venous O<sub>2</sub> saturation is 70%; the pulmonary capillary wedge O<sub>2</sub> saturation is 97%. The haemoglobin is normal and the patient is afebrile. You are able to state which of the following?  
a. her cardiac output is decreased  
b. her cardiac output is normal  
c. her heart is normal  
d. she has high output failure  
e. she is in shock due to a noncardiac cause
78. A 59 year old man who was active all his life develops sudden severe anterior chest pain that radiates to his back. Within minutes, he is unconscious. He has a history of hypertension, but a recent treadmill test had revealed no evidence of cardiac disease. Which of the following do you suspect?  
a. Acute viral myocarditis  
b. Group A streptococcal infection  
c. Pulmonary embolus  
d. Right middle cerebral artery embolus  
e. Tear in the aortic intima
79. Concerning complete atrioventricular septal defects which of the following statements is true?  
a. are seen frequently in patients with trisomy 21  
b. frequently have aortic valve insufficiency

- c. have a normal mitral valve structure  
 d. include a coronary sinus atrial septal defect  
 e. include a perimembranous ventricular septal defect
80. **21 year old woman has a history of palpitations and light headedness. ECG shows short PR interval and inferior Q waves. Her symptoms improve with atenolol 25 mg/day but she has had two short episodes of similar symptoms in the previous 24 hours. What is the longterm management of choice?**  
 a. Anticoagulation.  
 b. Oral amiodarone.  
 c. Oral digoxin.  
 d. Increase the dose of atenolol.  
 e. Radiofrequency ablation.
81. **A 60 year old man's echocardiogram shows a dilated left ventricular cavity with the remainder of the other chamber sizes normal. The most likely diagnosis is which of the following?**  
 a. aortic regurgitation  
 b. aortic stenosis  
 c. hypertensive heart disease  
 d. mitral regurgitation  
 e. mitral stenosis
82. **Left axis deviation is seen on the ECG in which of the following conditions?**  
 a. atrioventricular canal defects.  
 b. Ebstein's anomaly.  
 c. large ventricular septal defect.  
 d. patent ductus arteriosus.  
 e. tetralogy of Fallot.
83. **Which of the following is true regarding the action of Clopidogrel?**  
 a. It inhibits cyclooxygenase  
 b. It is an ADP receptor antagonist  
 c. It is a glycoprotein IIb/IIIa inhibitor  
 d. It is a selective factor Xa inhibitor  
 e. It is Hydroxymethyl Coenzyme A inhibitor
84. **Which ONE of the following is associated with Marfan's syndrome?**  
 a. Autosomal recessive inheritance  
 b. increased upper : lower body ratio  
 c. Mental retardation  
 d. Pulmonary stenosis  
 e. Retinal detachment
85. **A 30 year old intravenous drug abuser develops acute aortic regurgitation due to infective endocarditis. Which of the following is least likely to be found on clinical examination?**  
 a. decreased cardiac output  
 b. decrescendo diastolic murmur  
 c. hypotension  
 d. mitral valve preclosure  
 e. peripheral vasodilatation
86. **A 67 year old man presents with sudden onset atrial fibrillation (ventricular rate of 150/minute). His serum creatinine concentration was 250  $\mu\text{mol/L}$  (70110). What is the main factor that determines the choice of loading dose of digoxin in this patient?**  
 a. Absorption  
 b. Apparent volume of distribution  
 c. Lipid solubility  
 d. Plasma half-life  
 e. Renal clearance
87. **A 17 year old girl is short in stature for her age. She has not shown any changes of puberty. She has a webbed neck. Her vital signs include Temperature 36.6°C Respiratory rate 18/min Pulse 75 bpm and BP 165/85 mmHg. On physical examination, she has a continuous murmur heard over both the front of the chest as well as her back. Her lower extremities are cool with poor capillary filling. A chest radiograph reveals a prominent left heart border, no oedema or effusions, and rib notching. Which of the following pathologic lesions best explains these findings?**  
 a. Constriction of the aorta past the ductus arteriosus  
 b. Lack of development of the spiral septum and partial absence of conus musculature  
 c. Shortening and thickening of chordae tendineae of the mitral valve  
 d. Single large atrioventricular valve  
 e. Supravalvular narrowing in the aortic root
88. **Elevation of the jugular venous pressure during inspiration is most likely to be found in which of the following situations?**  
 a. a normal physical exam  
 b. cardiactamponade  
 c. constrictive pericarditis  
 d. dilated cardiomyopathy  
 e. myocarditis
89. **75 year old man with a history of anterior MI is taking amiodarone 400 mg/day for history of VT. He has a prolonged QT interval on his ECG. What is the most appropriate management?**  
 a. Admit to hospital for monitoring.  
 b. Atenolol.  
 c. Change amiodarone to flecainide.  
 d. Continue with amiodarone.  
 e. Discontinue amiodarone immediately.
90. **A 58 year old man has had an enlarging abdomen for several months. He has experienced no abdominal or chest pain. On physical examination he has a nontender abdomen with no masses palpable, but there is a fluid thrill. An abdominal Ultrasound Scan shows a large abdominal fluid collection with a small cirrhotic liver. A chest Xray shows a globally enlarged heart. Which of the following conditions is most likely to be present?**  
 a. Dilated cardiomyopathy  
 b. Lymphocytic myocarditis  
 c. Myocardial amyloid deposition  
 d. Nonbacterial thrombotic endocarditis  
 e. Severe occlusive coronary atherosclerosis
91. **Angina due to an imbalance between O<sub>2</sub> supply and demand without atherosclerosis would most likely be seen in which of the following circumstances?**  
 a. aortic regurgitation  
 b. cardiactamponade  
 c. pulmonary regurgitation  
 d. right heart failure  
 e. tricuspid regurgitation



1124 92. An 18 year old man had repeated episodes of breathlessness and palpitations, lasting about 20 minutes and resolving gradually. There were no abnormal physical signs. What is the most likely cause of these features?

- a. Drug abuse
- b. Panic disorder
- c. Paroxysmal supraventricular tachycardia
- d. Personality disorder
- e. Thyrotoxicosis

93. A previously well 60 year old lady is admitted with an Acute Anterior Myocardial Infarction. A random blood glucose concentration was found to be 12.1 mmol/L (<6.7). What is the optimal management of her blood sugar?

- a. Diet
- b. Gliclazide
- c. Intravenous insulin plus dextrose
- d. Metformin
- e. Subcutaneous insulin

94. A 65 year old was advised to start oral digoxin at a dose of 250 µg daily. His physician explained that the full effect of this treatment would not be apparent for at least a week. Which one of the following pharmacokinetic variables did the physician use to give this explanation?

- a. bioavailability
- b. half-life
- c. plasma protein binding
- d. renal clearance
- e. volume of distribution

95. A 75 year old lady presents with sudden breathlessness and palpitations. On examination, she was observed to have an irregular heart beat with rate of 140 bpm, BP 150/84 and normal heart sounds. On auscultation of the chest, fine basal crackles are heard. An ECG confirms AF and an old inferior MI. She is anticoagulated with heparin and given diuretics. Her heart rate remains rapid. What is the most appropriate management of the lady's AF?

- a. DCCV.
- b. IV amiodarone.
- c. IV beta-blocker.
- d. IV digoxin.
- e. Oral quinidine therapy.

96. A 45 year old female presents with a two day history of fever and joint pains. She has a past history of hypertension for which she is receiving antihypertensives. On examination she has a temperature of 38 Celsius, a facial rash and slight swelling with tenderness of the wrist and ankle joints. Which of the following antihypertensives may be responsible for her presentation.

- a. Minoxidil
- b. Phenoxybenzamine
- c. Hydralazine
- d. Alphamethyldopa
- e. Bendrofluazide

97. A 70 year old man with dilated cardiomyopathy remains symptomatic in NYHA class 2 due to chronic heart failure. On examination his pulse is 90 regular, BP 140/90, heart sounds normal, chest auscultation did not reveal any abnormalities. He is currently taking Lisinopril 30 mg OD and Frusemide 80 mg OD. What is the best treatment option?

- a. Amiodarone
- b. Carvedilol
- c. Digoxin

- d. Spironolactone
- e. Valsartan

98. A 40 year old man received an orthotopic cardiac transplant 7 years ago to treat a dilated cardiomyopathy. Since that time he has been healthy, with no episodes of rejection or infection. Over the next year, however, he develops fatigue with exercise. He has worsening pedal edema and orthopnea. On physical examination, his vital signs are Temperature 36.3°C, Pulse 78, Respiratory rate 16, and BP 130/70 mm Hg. There are no murmurs, rubs, or gallops audible. Bibasilar crackles in the lungs are audible. Which of the following conditions is most likely to account for these findings?

- a. Angiosarcoma
- b. Coronary arteriopathy
- c. Mitral valvular stenosis
- d. Myocarditis
- e. Pulmonary hypertension

99. Which of the following statements concerning the treatment of acute myocardial infarction is correct?

- a. A pansystolic murmur developing within the first 24 hours does not require further investigation.
- b. Dipyridamole therapy reduces reinfarction within the first year.
- c. Heparin is beneficial if given with streptokinase.
- d. Prophylactic lignocaine given in the first 48 hours is effective in preventing ventricular fibrillation
- e. Treatment with a dihydropyridine calcium antagonist is associated with increased cardiovascular mortality.

100. A 70 year old man is admitted with an acute Q wave inferior Myocardial Infarction. On day 5, he suddenly develops pulmonary oedema and a loud systolic murmur. Which of the following would be the most useful in establishing a diagnosis?

- a. chest X-ray
- b. coronary arteriography
- c. ECG
- d. right heart catheterisation and oximetry
- e. serum cardiac enzymes

101. A 65 year old man has long standing stable heart failure treated with frusemide and enalapril. He complains of swelling in his left knee and his GP treats him with Rofecoxib, a cyclooxygenase 2 (COX2) inhibitor. Two weeks later the patient has increasing breathlessness and ankle oedema. Which one of the following effects of rofecoxib is the most likely to explain his symptoms?

- a. decreased absorption of frusemide from the gut
- b. decreased myocardial contractility
- c. reduced effective action of enalapril
- d. the onset of anaemia
- e. the onset of fluid retention

102. Which of the following statements are true of coronary artery anatomy?

- a. Right bundle branch block in acute anterior myocardial infarction suggests obstruction prior to the first septal branch of the left anterior descending coronary artery
- b. the posterior descending artery is usually a branch of the circumflex artery
- c. The sinus node is supplied by a branch of the right coronary in over 90% of subjects.
- d. The AV node is supplied by the left anterior descending coronary artery.
- e. The left main stem is about 4 cm long

103. A 34 year old male presents with episodes of breathlessness on exertion. Examination reveals a loud P2 and fixed splitting of the second sound. Which of the following may be responsible for these signs?
- Maternal chicken pox infection
  - Maternal thalidomide therapy
  - 47 XXY karyotype
  - Homocystinuria
  - Excess maternal alcohol consumption
104. A 72 year old man presents with an episode of collapse. He has had two similar episodes recently, each lasting about one minute. Four years ago he suffered an anterior myocardial infarction. On examination he was orientated and symptom free with a regular pulse rate of 80 bpm, BP 140/80 mmHg and the apex beat was displaced to the left. There was an apical systolic murmur. There were no signs of trauma. ECG showed sinus rhythm, Q waves and ST segment elevation anteriorly without reciprocal depression. What is the diagnosis?
- acute anterior myocardial infarction
  - cerebrovascular accident
  - epileptic seizure
  - pulmonary embolism
  - ventricular tachycardia
105. Deficiency of which one of the following trace elements is implicated as a cause of cardiomyopathy?
- chromium
  - copper
  - manganese
  - selenium
  - zinc
106. A 40 year old man attending a routine screening has a blood pressure of 166/100 mmHg. Two weeks later his blood pressure was 150/90 mmHg. He does not smoke. He drinks 35 units alcohol / week. His body mass index (BMI) is 30 kg/m<sup>2</sup> (20-25). What is the best management strategy?
- amlodipine
  - atenolol
  - bendrofluzide
  - enalapril
  - lifestyle advice
107. A 78 year old female is referred by her GP with high blood pressure. Over the last three months her blood pressure is noted to be around 180/80 mmHg. She has a body mass index of 25.5 kg/m<sup>2</sup>, is a nonsmoker. There are no features to suggest a secondary cause for her hypertension. Which of the following is the most appropriate treatment for her blood pressure?
- Alpha Blocker
  - Angiotensin Converting Enzyme (ACE) Inhibitor
  - Angiotensin Blocker
  - Beta blocker
  - Calcium channel blocker
108. Which of the following compounds has a vasodilating effect?
- Antidiuretic hormone
  - Calcitonin
  - Endothelin
  - Renin
  - Somatostatin
109. A 14 year old boy presents with hypertension. Which of the following statements concerning hypertension in the young is true?
- Sodium nitroprusside is useful for the long term treatment of severe cases.
  - Headache is the usual presenting feature.
  - It is defined as systolic blood pressure above the 99th centile for age.
  - Abnormalities are frequently seen on DMSA scan.
  - Aortic coarctation is the commonest secondary cause.
110. A new antihypertensive drug needs to be investigated to establish its relative potency. Which of the following techniques is most appropriate for this purpose?
- bioassay
  - case control study
  - double blind, randomized, placebo controlled study
  - postmarketing surveillance
  - sequential trial
111. A 53 year old man presented with hypertension of 150/110 and is found to have the following results on investigation. Raised serum sodium, raised urinary potassium excretion and normal serum renin. What is the likely diagnosis?
- Adrenocortical adenoma
  - Coarctation of aorta
  - Malignant hypertension
  - Pheochromocytoma
  - Renal tumour
112. A 29 year old female who is 22 weeks pregnant is noted to have a blood pressure of 150/90 mmHg on 3 separate occasions. Urine protein is negative. Which of the following would be the first line treatment?
- alpha Methyl Dopa
  - Atenolol
  - Magnesium Sulphate
  - Nifedipine
  - Salbutamol
113. A 58 year old man presents with sudden onset chest pain. He has a known history of ischaemic heart disease. ECG shows ST segment elevation in V1-V5 without reciprocal depression. In which territory is the infarction most likely to have taken place?
- Anterior
  - Inferior
  - Lateral
  - Inferolateral
  - Posterior
114. A 54 year old male redevelops chest pain 72 hours after treatment for an anterior myocardial infarction. Which of the following markers will be the most sensitive in detecting reinfarction?
- CKMB
  - LDH
  - Myoglobin
  - Troponin I
  - Troponin T
115. Relationship between arterial blood pressure (BP), cardiac output (CO) and peripheral vascular resistance (PVR) can be described as
- $BP = CO \times PVR$
  - $BP = CO / PVR$

- c. BP = PVR/CO
- d. None of the above

116. If a fibrinolytic drug is used for treatment of acute myocardial infarction, the adverse drug effect that is most likely to occur is
- a. Acute renal failure
  - b. Development of antiplatelet antibodies
  - c. Encephalitis secondary to liver dysfunction
  - d. Hemorrhagic stroke
  - e. Neutropenia
117. Increased serum levels of which of the following may be associated with a decreased risk of atherosclerosis?
- a. Very low density lipoproteins (VLDL)
  - b. Low density lipoproteins (LDL)
  - c. Intermediate – density lipoproteins (IDL)
  - d. High density lipoproteins (HDL)
  - e. Cholesterol
118. If the patient has a history of gout, which of the following drugs is most likely to exacerbate this condition?
- a. Colestipol
  - b. Gemfibrozil
  - c. Lovastatin
  - d. Niacin
  - e. Simvastatin
119. After being counseled about lifestyle and dietary changes, the patient was started on atorvastatin. During his treatment with atorvastatin, it is important to routinely monitor serum concentrations of
- a. Blood urea nitrogen (BUN)
  - b. Alanine and aspartate aminotransferase
  - c. Platelets
  - d. Red blood cells
  - e. Uric acid
120. Six months after beginning atorvastatin, the patient's total and LDL cholesterol concentrations remained above normal and he continued to have anginal attacks despite good adherence to his antianginal medications. His physician decided for niacin. The major recognized mechanism of action of niacin is
- a. Decreased lipid synthesis in adipose tissue
  - b. Decreased oxidation of lipids in endothelial cells
  - c. Decreased secretion of VLDL by the liver
  - d. Increased endocytosis of HDL by the liver
  - e. Increased lipid hydrolysis by lipoprotein lipase
121. Following drugs act on imidazoline receptor
- a. Moxonidine
  - b. Dexmedetomidine
  - c. Tizanidine
  - d. All of the above
122. Which one of the following drugs increase digoxin plasma concentration by a pharmacokinetic mechanism?
- a. Captopril
  - b. Hydrochlorothiazide
  - c. Lidocaine
  - d. Quinidine
  - e. Sulfasalazine
123. A 55 year old patient currently receiving other drugs for another condition is to be started on diuretic therapy for mild heart failure. Thiazides are known to reduce the excretion of

- a. Diazepam
- b. Fluoxetine
- c. Imipramine
- d. Lithium
- e. Potassium

124. A hypertensive patient has been using nifedipine for some time without untoward effects. If he experiences a rapidly developing enhancement of the antihypertensive effect of the drug, it is probably due to
- a. Concomitant use of antacids
  - b. Foods containing tyramine
  - c. Grapefruit juice
  - d. Induction of drug metabolism
  - e. Over – the – counter decongestants
125. A drug lacking vasodilator properties that is useful in angina is
- a. Isosorbidedinitrate
  - b. Metoprolol
  - c. Nifedipine
  - d. Nitroglycerin
  - e. Verapamil
126. Which one of the following drugs is used in the treatment of male impotence and activates prostaglandin E1 receptors?
- a. Alprostadil
  - b. Fluoxetine
  - c. Mifepristone
  - d. Sildenafil
  - e. Zafirlukast
127. A treatment of angina that consistently decreases the heart rate and can prevent vasospastic angina attacks is
- a. Isosorbidedinitrate
  - b. Nifedipine
  - c. Nitroglycerin
  - d. Propranolol
  - e. Verapamil
128. In a patient receiving digoxin for congestive heart failure, condition that may facilitate the appearance of toxicity include
- a. Hyperkalemia
  - b. Hyponatremia
  - c. Hypocalcemia
  - d. Hypomagnesemia
  - e. All of the above
129. Activation of endothelin receptor ETA, leads to
- a. Vasoconstriction
  - b. Bronchoconstriction
  - c. Aldosterone release
  - d. All of the above
130. Methylxanthine drugs such as aminophylline cause which one of the following?
- a. Vasoconstriction in many vascular beds
  - b. Decrease in the amount of cAMP in mast cells
  - c. Bronchodilation
  - d. Activation of the enzyme phosphodiesterase
  - e. Sedation

131. **Drugs used in asthma that often cause tachycardia and tremor include**
- Beclomethasone
  - Cromolyn sodium
  - Ipratropium
  - Metaproterenol
  - All of the above
132. **Following potassium sparing diuretic inhibits action of aldosterone**
- Amiloride
  - Triamterene
  - Spironolactone
  - All of the above
133. **In patients with chronic granulomatous disease which of the following agents increases the synthesis of tumor necrosis factor, leading to activation of phagocytosis?**
- Aldesleukin
  - Cyclosporine
  - Filgrastim
  - Infliximab
  - Interferon gamma
134. **The mechanism of action of cyclosporine involves**
- Activation of calcineurin
  - Binding to cyclophilin to cause inhibition of a cytoplasmic phosphatase
  - Blockade of interleukin – 2receptors
  - Inhibition of phospholipase A2
  - Suppression of bone marrow progenitors
135. **Which one of the following drugs predictably prolongs the PR interval and increases cardiac contractility?**
- Digoxin
  - Lidocaine
  - Propranolol
  - Quinidine
  - Verapamil
136. **Which of the following is the drug of choice for management of cardiac arrhythmias that occur in digitalis toxicity?**
- Amiodarone
  - Lidocaine
  - Propranolol
  - Sotalol
  - Prazosin
137. **A 54yearoldwoman with severe hypercholesterolemia is to be treated with a combination of niacin and atorvastatin. With this drug combination, it is important that the patient be monitored closely for signs of**
- Agranulocytosis
  - Gallstones
  - Lactic acidosis
  - Myopathy
  - Thyrototoxicosis
138. **Regarding verapamil, which one of the following statements is false?**
- Angina pectoris is an important indication for the use of verapamil
  - Contraindicated in the asthmatic patient
  - Relaxes vascular smooth muscle
  - Slows the depolarization phase of the action potential in AV nodal cells
  - Used in management of supraventricular tachycardias
139. **What drug is used to prevent embolism in the lung and during myocardial infarction?**
- Alteplase
  - Human growth hormone
  - Granulocyte–macrophage colony – stimulating factor (GM-CSF)
  - EPOGEN (EPO)
  - None of the above
140. **Which of the following cardiovascular agents is classified chemically as a glycoside?**
- Nifedipine
  - Digoxin
  - Flecainide
  - Cholestyramine
  - Warfarin
141. **Inhibition of carbonic anhydrase results in**
- Abolition of  $\text{NaHCO}_3$  reabsorption in proximal tubule
  - Enhanced of  $\text{NaHCO}_3$  reabsorption in proximal tubule
  - Enhanced  $\text{NAHCO}_3$  secretion in distal tubule
  - None of the above
142. **Which of the following cyclotron produced radiopharmaceuticals is used for assessing regional myocardial perfusion as part of an exercise stress test?**
- Thallous chloride  $^{201}\text{Tl}$  USP
  - Sodium iodide  $^{123}\text{I}$
  - Gallium citrate  $^{67}\text{Ga}$  USP
  - Indium  $^{111}\text{In}$  pentetate
  - Cobalt  $^{57}\text{Co}$  cyanocobalamin
143. **Mary has a family history of heart disease and wonders if garlic would be beneficial to her. Which of the following statements is correct about garlic?**
- Entericcoatedtablets release their contents in the stomach
  - Side effects include heartburn, flatulence, and sweating
  - The safety of garlic in pregnancy is unknown
  - Garlic does not interact with warfarin
144. **Exertion–induced angina, which is relieved by rest, nitroglycerin, or both, is referred to as**
- Prinzmetal’s angina
  - Unstable angina
  - Classic angina
  - Variant angina
  - Preinfarction angina
145. **Myocardial oxygen demand is increased by all of the following factors except**
- Exercise
  - Smoking
  - Cold temperatures
  - Isoproterenol
  - Propranolol
146. **Which of the following agents used in Prinzmetal’s angina has spasmolytic actions, which increase coronary blood supply?**
- Nitroglycerin
  - Nifedipine

- c. Timolol
- d. Isosorbide mononitrate
- e. Propranolol

147. The oral absorption of following osmotic diuretic is negligible

- a. Glycerin
- b. Mannitol
- c. Isosorbide
- d. All of the above

148. Maximal medical therapy for treating angina pectoris is represented by which of the following choices?

- a. Diltiazem, verapamil, nitroglycerin
- b. Atenolol, isoproterenol, diltiazem
- c. Verapamil, nifedipine, propranolol
- d. Isosorbide, atenolol, diltiazem
- e. Nitroglycerin, isosorbide, atenolol

149. The term ischemic heart disease (IHD) is used to designate all of the following conditions except

- a. Angina pectoris
- b. Sudden cardiac death
- c. Congestive heart failure (CHF)
- d. Arrhythmias

150. Which of the following thrombolytic agents would be appropriate at this time?

- a. Anisoylated plasminogen streptokinase activator complex (APSAC)
- b. Streptokinase (SK)
- c. Recombinant tissue plasminogen activator (tPA)

151. Strong anticholinergic effects limit the antiarrhythmic use of

- a. Quinidine
- b. Procainamide
- c. Tocainide
- d. Flecainide
- e. Disopyramide

152. Following loop diuretic is a phenoxy acetic acid derivative

- a. Furosemide
- b. Bumetanide
- c. Ethacrynic acid
- d. All of the above

153. Following potassium sparing diuretic is a mineralocorticoid receptor antagonist

- a. Amiloride
- b. Triamterene
- c. Spironolactone
- d. All of the above

154. A patient receiving a class I antiarrhythmic agent on a chronic basis complains of fatigue, low grade fever, and joint pain suggestive of systemic lupus erythematosus (SLE). The patient is most likely receiving

- a. Lidocaine
- b. Procainamide
- c. Quinidine
- d. Flecainide
- e. Propranolol

155. Which of the following drugs is a class IV antiarrhythmic that is primarily indicated for the treatment of supraventricular tachyarrhythmias?

- a. Lbutilide
- b. Mexiletine
- c. Diltiazem
- d. Quinidine
- e. Propranolol

156. Which of the following agents has a direct effect on the AV node, delaying calcium channel depolarization?

- a. Lidocaine
- b. Diltiazem
- c. Bretylium
- d. Quinidine
- e. Lbutilide

157. Which of the following groups of symptoms is most often associated with a patient who has right-sided heart failure?

- a. Nocturia, rales, paroxysmal nocturnal dyspnea
- b. Paroxysmal nocturnal dyspnea, pedal edema, jugular venous distention, hepatjugular reflux
- c. Jugular venous distention, hepatjugular reflux, pedal edema, shortness of breath
- d. Hepatjugular reflux, jugular venous distention, pedal edema, abdominal distention
- e. Paroxysmal nocturnal dyspnea, jugular venous distention, abdominal distention, shortness of breath

158. Which of the following combinations of drugs, when used together, reduce both preload and afterload?

- a. Nitroglycerin and isosorbidedinitrate
- b. Hydralazine and isosorbidedinitrate
- c. Captopril and methyldopa
- d. Prazosin and angiotension II
- e. Hydralazine and methyldopa

159. When digoxin is used in a patient with congestive heart failure (CHF), it works by exerting a positive effect on

- a. Stroke volume
- b. Total peripheral resistance
- c. Heart rate
- d. Blood pressure
- e. Venous return

160. Because of proven beneficial effects on "cardiac remodeling", these agents are now indicated as first line therapy in CHF patients. Which of the following is representative of this group of drugs?

- a. Hydrochlorothiazide
- b. Enalapril
- c. Furosemide
- d. Carvedilol
- e. Bumetanide

161. For treating the patient with congestive heart failure (CHF), which of the following dosages of dopamine is selected for its positive inotropic effects?

- a. 2.0 mg/kg/min
- b. 5–10 mg/kg/min
- c. 10–20 mg/kg/min
- d. 40 mg/kg/min
- e. 40 mg/kg/min

162. Milrinone is an example of

- a. Phosphodiesterase I inhibitor
- b. Phosphodiesterase II inhibitor

- c. Phosphodiesterase III inhibitor  
d. Phosphodiesterase IV inhibitor
163. **Situations that predispose a digitalis-treated patient to toxicity include**
- Hypercalcemia
  - Hyperkalemia
  - Hypermagnesemia
164. **Unfractionated heparin binds to antithrombin III and inactivates clotting factor(s)**
- Xa
  - Ixa
  - Iia
  - All of the above
  - None of the above
165. **A patient to be commenced on oral anticoagulant therapy for DVT would be treated with**
- Oral anticoagulant therapy with warfarin for a goal international normalized ration (INR) of 2–3
  - Oral anticoagulant therapy with warfarin for a goal INR of 2.5–3.5
  - Oral anticoagulant therapy with aspirin for a goal INR of 2–3
166. **A patient on oral anticoagulant therapy is commenced on sulfamethoxazole-trimethoprim, double-strength twice daily. One may expect to see the international normalized ratio**
- Increase
  - Decrease
  - Remain unchanged
167. **When compared to unfractionated heparin, low molecular weight heparins have**
- Preferential binding affinity to factor Xa relative to Iia (thrombin)
  - Shorter half-lives
  - Dose – dependent renal clearance
168. **Acute renal failure (ARF) may be caused by all of the following except**
- Acute tubular necrosis (ATN) due to drug therapy (e.g., aminoglycosides, contrast media)
  - Severe hypotension or circulatory collapse
  - Decreased cardiac output, as from congestive heart failure
  - Hemolysis, myoglobinuria
  - Hyperkalemia
169. **During Phase 2 of action potential in cardiac cell, depolarizing current through calcium channels is balanced by**
- Delayed rectifier potassium current
  - outward chloride channel
  - Both (a) and (b)
  - None of the above
170. **The action of quinidine differs from that of digitalis in**
- Decreasing irritability of cardiac muscle
  - Preventing passage of impulses to the ventricle
  - Increasing irritability of heart muscle
  - Reducing conductivity
  - None of the above
171. **Overuse of digitalis may result in**
- Habituation
  - Tolerance
  - Addiction
  - Physical dependence
  - Cummulative poisoning
172. **The action of digitalis is enhanced by**
- Sodium
  - Calcium
  - Magnesium
  - Potassium
  - Chloride
173. **In case of acute pain of angina pectoris the most effective treatment would be to administer**
- Mannitolhexanitate
  - Erythryltetranitrate
  - Sodium nitrate
  - Pentaerythritoltetranitrate
  - Nitroglycerin
174. **Which of the following is used to lower blood lipid levels?**
- Trimethadione
  - Clofibrate
  - Flucytosine
  - Coumarin
  - Propranolol
175. **The chief use of levoarterenol is to treat**
- Shock
  - Diabetes
  - Hypertension
  - Cardiac arrhythmias
  - Iron deficiencies
176. **Tolerance to nitroglycerin may be overcome by**
- Initially using the largest safe dose of the drug
  - Using other nitrites
  - Temporarily discontinuing the drug for one or two weeks
  - Use of higher doses
  - None of the above
177. **Quinidine can cause paradoxical tachycardia in a patient of**
- Stick sinus syndrome
  - Auricular extrasystoles
  - Auricular fibrillation
  - Ventricular extrasystoles
178. **Quinidine is now used primarily for**
- Conversion of auricular fibrillation to sinus rhythm
  - Control of ventricular rate in atrial flutter
  - Termination of ventricular tachycardia
  - Prevention of recurrences of atrial and ventricular extrasystoles/tachycardias
179. **Procainamide differs from quinidine in the following respect**
- It does not cause paradoxical tachycardia
  - It has no alfa adrenergic blocking activity
  - It has little antivagal action
  - Both (b) and (c)
180. **In heart, potassium channels determine**
- Pacemaker function
  - Resting potential

- c. Action potential duration  
d. All of the above
181. Lidocaine is the preferred antiarrhythmic for emergency control of cardiac arrhythmias following acute myocardial infarction because
- It has a rapidly developing and titratable antiarrhythmic action
  - It causes little myocardial depression and hypotension
  - It has broad spectrum antiarrhythmic efficacy in atrial as well as ventricular arrhythmias
  - Both (a) and (b)
182. Hypothyroidism is a possible consequence of prolonged therapy with
- Procainamide
  - Mexiletine
  - Sotalol
  - Amioiv
183. Which of the following drugs is preferred for termination of paroxysmal supraventricular tachycardia
- Digoxin
  - Quinidine
  - Propranolol
  - Verapamil
184. The following drug is used to reduce the frequency of angina pectoris as well as to terminate an acute attack
- Digoxin
  - Furosemide
  - Enalapril
  - Amrinone
185. Antianginal drugs afford the following benefit/benefits
- Terminate anginal attacks
  - Decrease the frequency of anginal attacks
  - Retard the progression of coronary artery disease
  - Both (a) and (b)
186. Choose the correct statement about the action of nitrates on coronary vessels
- They mitigate angina pectoris by increasing total coronary flow
  - They preferentially dilate conducting arteries without affecting resistance arterioles
  - They preferentially dilate autoregulatory arterioles without affecting the larger arteries
  - They increase subepicardial blood flow without affecting subendocardial blood flow
187. Organic nitrates relax vascular smooth muscle by
- Increasing intracellular cyclic AMP
  - Increasing intracellular cyclic GMP
  - Decreasing intracellular cyclic AMP
  - Both (b) and (c)
188. Select the organic nitrate which undergoes minimal firstpassmetabolism in the liver
- Glyceryltrinitrate
  - Isosorbidedinitrate
  - Isosorbidemononitrate
  - Erythryltetranitrate
189. The primary mechanism of beneficial effect of glyceryltrinitrate in classical angina pectoris is
- Increase in total coronary blood flow
  - Redistribution of coronary blood flow
  - Reduction of cardiac preload
  - Reduction of cardiac after load
190. Enhanced automaticity in cardiac cells may occur because of
- βadrenergic stimulation
  - Hypokalemia
  - Mechanical stretch of cardiac muscles
  - All of the above
191. Glyceryltrinitrate is administered by all of the following routes except
- Oral
  - Sublingual
  - Intramuscular
  - Intravenous
192. A patient of acute myocardial infarction being treated in intensive care unit developed left ventricular failure with raised central venous pressure. It was decided to use glyceryltrinitrate. Which route/method of administration would be most suitable.
- Sublingual
  - Oral
  - Intravenous bolus injection
  - Slow
193. A patient suffers from episodic pain diffusely localized over the chest and upper abdomen, which is relieved by sublingual glyceryltrinitrate. He could be suffering from
- Angina pectoris
  - Biliary colic
  - Esophageal spasm
  - All of the above
194. The dihydropyridines block the following type of calcium channels.
- Ltypevoltage sensitive channels
  - Ttypevoltage sensitive channels
  - Ntypevoltage sensitive channels
  - Receptor operated calcium channels
195. Which of the following drugs is most likely to accentuate variant (Prinzmetal) angina ?
- Digoxin
  - Furosemide
  - Enalapril
  - Amrinone
196. In cardiac cells, adenosine
- Causes shortening of action potential duration
  - Depolarization
  - Increase in normal automaticity
  - All of the above
197. Which of the following antianginal drugs is most likely to produce tachycardia as a side effect ?
- Amlodipine
  - Nifedipine
  - Diltiazem
  - Verapamil

198. Which of the following is not an attribute of amlodipine ?
- High and consistent oral bioavailability
  - Large volume of distribution
  - Generation of an active metabolite
  - Long elimination half-life
199. Propranolol should not be prescribed for a patient of angina pectoris who is already receiving
- Nifedipine
  - Felodipine
  - Verapamil
  - Isosorbide mononitrate
200. Which of the following drugs is a potassium channel opener ?
- Pinacidil
  - Hydralazine
  - Glibenclamide
  - Amiloride
201. Though nitrates and calcium channel blockers are both vasodilators, they are used concurrently in angina pectoris because
- They antagonize each other's side effects
  - Nitrates primarily reduce preload while calcium channel blockers primarily reduce afterload
  - Nitrates increase coronary flow while calcium
  - Both (b) and (c)
202. Coronary steal phenomenon has been noted most frequently with
- Glyceryl trinitrate
  - Dipyridamole
  - Propranolol
  - Diltiazem
203. Which of the following drugs is believed to improve microcirculation in peripheral vascular diseases by promoting RBC flexibility ?
- Cyclandelate
  - Theophylline
  - Pentoxifylline
  - Nicotinic acid
204. Higher incidence of myocardial infarction and increased mortality has been noted with the use of the following antihypertensive drug
- Nifedipine
  - Verapamil
  - Diltiazem
  - Lisinopril
205. Cardiac glycosides are obtained from following plant source.
- Rauwolfiaserpentina
  - Strophanthusgratus
  - Ricinuscommunis
  - Atropa belladonna
206. Therapeutic dose of digoxin in a normal individual has the following effects, except
- Increase in the speed of myocardial contractility
  - No significant change in cardiac output
  - Relaxation of peripheral vascular bed
  - Increase in the force of myocardial contractility
207. Digoxin given for cardiac failure is extremely valuable in 1131 patients of
- Thyrotoxicosis
  - Beriberi
  - Cor pulmonale
  - Atrial fibrillation
208. The agent given sublingually in an acute attack of angina pectoris is
- Glyceryl trinitrate
  - Amyl nitrite
  - Erythritol tetranitrate
  - Pentaerythritol tetranitrate
209. Following statement is true about lidocaine
- Reduce the slope of Phase 4
  - Threshold excitability is not altered
  - Action potential is not affected
  - All of the above
210. Aspirin in small doses (50 to 150 mg per day)
- Is of benefit in patients of unstable angina
  - Has thrombolytic action
  - PREFERentially inhibits prostacyclin synthetase enzyme
  - MAY Alleviate need for Verapamil in variant angina
211. Major beneficial effect of nitrates in classical angina is due to
- Dilation of veins more than arteries
  - Increase in total coronary blood flow
  - An increase in the end diastolic size of the heart
  - An increase in the heart rate
212. Major lipid class present in chylomicrons is
- Endogenous triglycerides
  - Cholesterol esters
  - Dietary triglycerides
  - All of the above
213. A 65-year-old man presents with central crushing chest pain for the first time. He is transferred immediately to the closest cardiac unit to undergo a primary percutaneous coronary intervention. There is thrombosis of the left circumflex artery only. Angioplasty is carried out and a drug-eluting stent is inserted. What are the most likely changes to have occurred on ECG during admission?
- ST depression in leads V1-4
  - ST elevation in leads V1-6
  - ST depression in leads II, III and AVF
  - ST elevation in leads V5-6
  - ST elevation in leads II, III and AVF
214. A 78-year-old woman is admitted with heart failure. The underlying cause is determined to be aortic stenosis. Which sign is most likely to be present?
- Pleural effusion on chest x-ray
  - Raised jugular venous pressure (JVP)
  - Bilateral pedal oedema
  - Bibasilar crepitations
  - Atrial fibrillation
215. A patient is admitted with pneumonia. A murmur is heard on examination. What finding points to mitral regurgitation?
- Murmur louder on inspiration
  - Murmur louder with patient in left lateral position



- c. Murmur louder over the right 2nd intercostal space midclavicular line
- d. Corrigan's sign
- e. Narrow pulse pressure
216. A 79-year-old woman is admitted to the coronary care unit (CCU) with unstable angina. She is started on appropriate medication to reduce her cardiac risk. She is hypertensive, fasting glucose is normal and cholesterol is 5.2. She is found to be in atrial fibrillation. What is the most appropriate treatment?
- Aspirin and clopidogrel
  - Digoxin
  - Cardioversion
  - Aspirin alone
  - Warfarin
217. A 55-year-old man has just arrived in complaining of 20 minutes of central crushing chest pain. Which feature is most indicative of myocardial infarction at this moment in time?
- Inverted T waves
  - ST depression
  - ST elevation
  - Q waves
  - Raised troponin
218. A 66-year-old woman presents to with a 2-day history of shortness of breath. The patient notes becoming progressively short of breath as well as a sharp pain in the right side of the chest which is most painful when taking a deep breath. The patient also complains of mild pain in the right leg, though there is nothing significant on full cardiovascular and respiratory examination. Heart rate is 96 and respiratory rate is 12. The patient denies any weight loss or long haul flights but mentions undergoing a nasal polypectomy 3 weeks ago. The most likely diagnosis is:
- Muscular strain
  - Heart failure
  - Pneumothorax
  - Angina
  - Pulmonary embolism
219. A 59-year-old man presents for a well person check. A cardiovascular, respiratory, gastrointestinal and neurological examination is performed. No significant findings are found, except during auscultation a mid systolic click followed by a late systolic murmur is heard at the apex. The patient denies any symptoms. The most likely diagnosis is:
- Barlow syndrome
  - Austin Flint murmur
  - Patent ductus arteriosus
  - Graham Steell murmur
  - Carey Coombs murmur
220. A 60-year-old man presents to with a 3-day history of increasingly severe chest pain. The patient describes the pain as a sharp, tearing pain starting in the centre of his chest and radiating straight through to his back between his shoulder blades. The patient looks in pain but there is no pallor, heart rate is 95, respiratory rate is 20, temperature 37°C and blood pressure is 155/95 mmHg. The most likely diagnosis is:
- Myocardial infarction
  - Myocardial ischaemia
  - Aortic dissection
  - Pulmonary embolism
  - Pneumonia
221. A 49-year-old man is rushed to complaining of a 20-minute history of severe, crushing chest pain. After giving the patient glyceryl trinitrate (GTN) spray, he is able to tell you he suffers from hypertension and type 2 diabetes and is allergic to aspirin. The most appropriate management is:
- Aspirin
  - Morphine
  - Heparin
  - Clopidogrel
  - Warfarin
222. While on call you are called by a nurse to a patient on the ward complaining of light headedness and palpitations. When you arrive the patient is not conscious but has a patent airway and is breathing with oxygen saturation at 97 per cent. You try to palpate a pulse but are unable to find the radial or carotid. The registrar arrives and after hearing your report of the patient decides to shock the patient who recovers. What is the patient most likely to have been suffering?
- Torsades de Pointes
  - Ventricular fibrillation
  - Sustained ventricular tachycardia
  - Non-sustained ventricular tachycardia
  - Normal heart ventricular tachycardia
223. A 67-year-old man presents to with a 3-day history of shortness of breath. On examination you palpate the radial pulse and notice that the patient has an irregular heart beat with an overall rate of 140 bpm. You request an electrocardiogram (ECG) which reveals that the patient is in atrial fibrillation. Which of the following would you expect to see when assessing the JVP?
- Raised JVP with normal waveform
  - Large 'v waves'
  - Cannon 'a waves'
  - Absent 'a waves'
  - Large 'a waves'
224. A 78-year-old woman is admitted to your ward following a 3-day history of shortness of breath and a productive cough of white frothy sputum. On auscultation of the lungs, you hear bilateral basal coarse inspiratory crackles. You suspect that the patient is in congestive cardiac failure. You request a chest x-ray. Which of the following signs is not typically seen on chest x-ray in patients with congestive cardiac failure?
- Lower lobe diversion
  - Cardiomegaly
  - Pleural effusions
  - Alveolar oedema
  - Kerley B lines
225. A 56-year-old man presents to your clinic with symptoms of exertional chest tightness which is relieved by rest. You request an ECG which reveals that the patient has first degree heart block. Which of the following ECG abnormalities is typically seen in first degree heart block?
- PR interval >120 ms
  - PR interval <300 ms
  - PR interval <200 ms
  - PR interval >200 ms
  - PR interval <120 ms
226. You see a 57-year-old woman who presents with worsening shortness of breath coupled with decreased exercise tolerance. She had rheumatic fever in her adolescence and suffers from essential hypertension. On examination she has signs which point to a diagnosis of mitral stenosis. Which of the following is not a clinical sign associated with mitral stenosis?

- a. Malar flush  
 b. Atrial fibrillation  
 c. Pan-systolic murmur which radiates to axilla  
 d. Tapping, undisplaced apex beat  
 e. Right ventricular heave
227. A 48-year-old woman has been diagnosed with essential hypertension and was commenced on treatment three months ago. She presents to you with a dry cough which has not been getting better despite taking cough linctus and antibiotics. You assess the patient's medication history. Which of the following antihypertensive medications is responsible for the patient's symptoms?
- a. Amlodipine  
 b. Lisinopril  
 c. Bendroflumethiazide  
 d. Frusemide  
 e. Atenolol
228. A 62-year-old male presents with palpitations, which are shown on ECG to be atrial fibrillation with a ventricular rate of approximately 130/minute. He has mild central chest discomfort but is not acutely distressed. He first noticed these about 3 hours before coming to hospital. As far as is known this is his first episode of this kind. Which of the following would you prefer as first-line therapy?
- a. Anticoagulate with heparin and start digoxin at standard daily dose  
 b. Attempt DC cardioversion  
 c. Administer bisoprolol and verapamil, and give warfarin  
 d. Attempt cardioversion with IV flecainide  
 e. Wait to see if there is spontaneous reversion to sinus rhythm
229. A 76-year-old male is brought to after collapsing at home. He has recovered within minutes and is fully alert and orientated. He says this is the first such episode that he has experienced, but describes some increasing shortness of breath in the previous six months and brief periods of central chest pain, often at the same time. On examination, blood pressure is 115/88 mmHg and there are a few rales at both bases. On ECG there are borderline criteria for left ventricular hypertrophy. Which of the following might you expect to find on auscultation?
- a. Mid-diastolic murmur best heard at the apex  
 b. Crescendo systolic murmur best heard at the right sternal edge  
 c. Diastolic murmur best heard at the left sternal edge  
 d. Pan-systolic murmur best heard at the apex  
 e. Pan-systolic murmur best heard at the left sternal edge
230. A 63-year-old male was admitted to 2 days after discharge following an apparently uncomplicated MI. He complained of rapidly worsening shortness of breath over the previous 48 hours but no further chest pain. He was tachypnoeic and had a regular pulse of 110/minute, which proved to be sinus tachycardia. The jugular venous pressure was raised and a pan-systolic murmur was noted, maximal at the left sternal edge. Which of the following is the most likely diagnosis?
- a. Mitral incompetence  
 b. Ventricular septal defect  
 c. Aortic stenosis  
 d. Dressler's syndrome  
 e. Further myocardial infarction
231. A 57-year-old male is admitted complaining of headaches and blurring of vision. His blood pressure is found to be 240/150 mmHg and he has bilateral papilloedema, but is fully orientated and coherent. He had been known to be hypertensive for about five years and his blood pressure control had been good on three drugs. However, he had decided to stop all medication two months before this event. Which of the following would be your preferred parenteral medication at this point?
- a. Glyceryltrinitrate  
 b. Hydralazine  
 c. Labetalol  
 d. Sodium nitroprusside  
 e. Phentolamine
232. A 16-year-old male is referred for assessment of hypertension. On average, his blood pressure is 165/85 mmHg, with radiofemoral delay. There is a mid-systolic murmur maximal at the aortic area, and radiating to the back. Clinical findings and the ECG are compatible with left ventricular hypertrophy. What is the most likely underlying pathology?
- a. Hypertrophic obstructive cardiomyopathy  
 b. Congenital aortic stenosis  
 c. Coarctation of the aorta  
 d. Patent ductus arteriosus  
 e. Atrial septal defect
233. A 16-year-old boy is diagnosed with a small ventricular septal defect, having been screened by echocardiography because of a family history of hypertrophic obstructive cardiomyopathy. He is entirely asymptomatic, plays several sports regularly and has no growth retardation. The echocardiogram also confirms a small left to right shunt, with pulmonary to systemic flow ratio only just above one. Which of the following is the most likely to be a significant complication of his condition?
- a. Pulmonary hypertension  
 b. Heart failure  
 c. Dysrhythmias  
 d. Endocarditis  
 e. Shunt reversal (right to left flow)
234. A 52 year-old woman has been treated for several years with amlodipine and lisinopril for what has been presumed to be primary hypertension. She is seen by her GP having complained of persistent left loin pain. Her BP is 150/95 mmHg. She is tender in the left loin and both kidneys appear to be enlarged. On urine dipstick testing, there is microscopic haematuria. Which of the following is likely to be the most appropriate investigation at this point?
- a. Urinary tract ultrasound  
 b. Abdominal and pelvic computed tomography (CT) scan  
 c. Microscopy of the urine (microbial and cytological)  
 d. Renal biopsy  
 e. Intravenous urogram
235. A 61-year-old man presents with a 2-hour history of moderately severe retrosternal chest pain, which does not radiate and is not affected by respiration or posture. He complains of general malaise and nausea, but has not vomited. His ECG shows ST segment depression and T wave inversion in the inferior leads. Troponin levels are not elevated. He has already been given oxygen, aspirin and intravenous GTN; he is an occasional user of sublingual GTN and takes regular bisoprolol for stable angina. What would be the most appropriate next step in his management?
- a. IV low-molecular weight heparin  
 b. Thrombolysis with alteplase  
 c. IV nicardapine  
 d. Angiography with stenting  
 e. Oral clopidogrel

**1134 236.** A 41-year-old woman is referred for assessment after suffering a second pulmonary embolus within a year. She has not been travelling recently, has not had any surgery, does not smoke and does not take the oral contraceptive pill. She is not currently on any medication as the diagnosis is retrospective and she is now asymptomatic. What should be the next step in her management?

- Initiation of warfarin therapy
- ECG
- Thrombophilia screen
- Insertion of inferior vena cava filter
- Duplex scan of lower limb veins and pelvic ultrasound

**237.** A 32-year-old woman attends her GP for a routine medical examination and is noted to have a mid-diastolic murmur with an opening snap. Her blood pressure is 118/71 mmHg and the pulse is regular at 66 beats per minute. She is entirely asymptomatic and chest x-ray and ECG are normal. What would be the most appropriate investigation at this point?

- ECG
- Anti-streptolysin O titre
- Cardiac catheterization
- Thallium radionuclide scanning
- Colour Doppler scanning

**238.** A 46-year-old man develops sudden severe central chest pain after lifting heavy cases while moving house. The pain radiates to the back and both shoulders but not to either arm. His BP is 155/90 mmHg, pulse rate is 92 beats per minute and the ECG is normal. He is distressed and sweaty, but not nauseated. What would you consider the most likely diagnosis?

- Pneumothorax
- MI
- Pulmonary embolism
- Aortic dissection
- Musculoskeletal pain

**239.** A 49-year-old woman presents with increasing shortness of breath on exertion developing over the past three months. She has no chest pain or cough, and has noticed no ankle swelling. On examination, blood pressure is 158/61 mmHg, pulse is regular at 88 beats per minute and there are crackles at both lung bases. There is a decrescendo diastolic murmur at the left sternal edge. What is the most likely diagnosis?

- Aortic regurgitation
- Aortic stenosis
- Mitral regurgitation
- Mitral stenosis
- Tricuspid regurgitation

**240.** A 21-year-old man is on his way home from a party when he experiences the sudden onset of rapid palpitations. He feels uncomfortable but not short of breath and has no chest pain. He goes to the nearest department, where he is found to have a supraventricular tachycardia (SVT) at a rate of 170/minute. Carotid sinus massage produced transient reversion to sinus rhythm, after which the tachycardia resumed. What would be the next step in your management?

- Repeat carotid sinus massage
- IV verapamil
- IV propranolol
- IV adenosine
- Synchronized DC cardioversion

**241.** A 44-year-old woman attends her local department with a history of at least six months of frequent central chest pain in the early morning or during the night. She had no chest pain on exertion. This had been a particularly severe attack,

lasting over 2 hours. Her pulse rate is 84/minute in sinus rhythm, and blood pressure is 134/86 mmHg. The ECG shows anterior ST segment elevation, but troponin levels do not rise. Subsequent coronary angiography is normal. What is the most likely diagnosis?

- MI
- Stable angina
- Unstable angina
- Anxiety
- Variant angina

**242.** A previously fit 19-year-old man presents with unusual shortness of breath on exertion. At times, this is also associated with central chest pain. On examination there is a loud mid-systolic murmur at the left sternal edge. Heart rate and blood pressure are normal and there is no oedema. The ECG shows left axis deviation and the voltage criteria for left ventricular hypertrophy and the echocardiogram reveals a significant thickened interventricular septum, with delayed ventricular filling during diastole. There is a family history of sudden death below the age of 50. Which of the following would be your initial therapy?

- Digoxin
- Long-acting nitrates
- Beta-blockers
- Rate-limiting calcium channel blockers
- Partial excision of the septum

**243.** A 44-year-old woman presents with episodes of headaches, associated with anxiety, sweating and a slow pulse rate. At the time of her initial consultation, her blood pressure was 150/95 mmHg seated, but 24 hour ambulatory monitoring shows a peak of 215/130 mmHg, associated with the symptoms described above. Which of the following would be your initial diagnostic procedure?

- Magnetic resonance imaging (MRI) scans of the abdomen and pelvis
- Measurement of random plasma catecholamines
- Measurement of urinary metanephrines over several 24 hour periods
- Glucose tolerance test
- Pharmacological provocation using clonidine

**244.** A 56-year-old man presents to the department with a 2-hour history of central chest pain radiating to the left arm. He is anxious, nauseated and sweaty. His pulse rate is 120/minute in sinus rhythm and the ECG reveals ST elevation in leads II, III and aVF. The troponin level is significantly raised. This is certainly acute MI. Which is the most likely coronary vessel to be occluded?

- Circumflex artery
- Left anterior descending artery
- Right coronary artery
- Left main coronary artery
- Posterior descending artery

**245.** A 45-year-old woman complains of increasing shortness of breath on exertion, as well as orthopnoea, for the previous 3–4 months. She had apparently recovered from pericarditis about a year earlier. On ECG there is low voltage, especially in the limb leads, and the chest x-ray shows pericardial calcification. The presumptive diagnosis is constrictive pericarditis. Which of the following physical signs would be consistent with this?

- Increased jugular distention on inspiration
- Third heart sound
- Fourth heart sound
- Rales at both lung bases
- Loud first and second heart sounds

246. A 71-year-old man is being treated for congestive heart failure with a combination of drugs. He complains of nausea and anorexia, and has been puzzled by observing yellow rings around lights. His pulse rate is 53/minute and irregular and blood pressure is 128/61 mmHg. Which of the following medications is likely to be responsible for these symptoms?
- Lisinopril
  - Spironolactone
  - Digoxin
  - Furosemide
  - E. Bisoprolol
247. A 29-year-old woman goes to see her GP complaining of fatigue and palpitations. She says she has also lost weight, though without dieting. On examination, her pulse rate is approximately 120/min and irregularly irregular. Her blood pressure is 142/89 mmHg and her body mass index is 19. There are no added cardiac sounds. The ECG confirms the diagnosis of atrial fibrillation. What would you suggest as the most useful next investigation.
- Thyroid function tests (TSH, free T4)
  - ECG
  - Chest x-ray
  - Full blood count
  - Fasting blood sugar
248. A 58-year-old man has made an excellent functional recovery after an anterior MI. He is entirely asymptomatic and there is no abnormality on physical examination. His blood pressure is 134/78 mmHg and he is undertaking a cardiac rehabilitation programme. Which of the following would you not recommend as part of his secondary prevention planning?
- Aspirin
  - Lisinopril
  - Simvastatin
  - Bisoprolol
  - Omega-3 fatty acids
249. A 25-year-old woman with known mitral valve prolapse develops a low grade fever, malaise and night sweats within a couple of weeks of a major dental procedure. Examination reveals a pulse rate of 10/minute, which is regular, tender vasculitic lesions on the finger pulps and microscopic haematuria. Which investigation is most likely to provide a definitive diagnosis?
- Full blood count
  - ECG
  - Autoantibody screen
  - Blood culture
  - Coronary angiography
250. An asymptomatic 31-year-old woman has been referred for cardiological assessment. After her ECG she was told that she had mitral valve prolapse and would like further information on this condition. Which of the following statements is correct?
- Beta-blocker therapy is indicated
  - Angiotensin-converting enzyme (ACE) inhibitor therapy is indicated
  - One or both leaflets of the mitral valve are pushed back into the left atrium during systole
  - Significant mitral regurgitation will eventually develop
  - Exercise should be restricted
251. A 69-year-old woman complains of intermittent palpitations, lasting several hours, which then stop spontaneously. She also suffers from asthma. Holter monitoring confirms paroxysmal atrial fibrillation. Which of the following statements is correct regarding the management of this patient?
- Digoxin effectively prevents recurrence of the arrhythmia
  - Anticoagulation is not necessary
  - Sotalol may be effective
  - Amiodarone should be avoided
  - Flecainide orally may be an effective as-needed treatment to abort an Attack
252. A 57-year-old man is reviewed in a hypertension clinic, where it is found that his blood pressure is 165/105 mmHg despite standard doses of amlodipine, perindopril, doxazosin and bendroflumethiazide. Electrolytes and physical examination have been, and remain, normal. Which of the following would be your next stage in his management?
- Arrange for his medication to be given under direct observation
  - Add spironolactone to his medication
  - Arrange urinary catecholamine assays
  - Request an adrenal CT scan
  - Add verapamil to his medication
253. Cardiac toxicity is seen most in
- Bleomycin
  - Adriamycin
  - Methotrexate
  - Busulphan
254. Cardiospasm is
- Coronary artery stenosis
  - Presbyoesophagus
  - Esophageal webs
  - Cricoid narrowing
255. Carotid sinus massage produces
- Reflex bradypnea
  - Reflex bradycardia
  - Reflex tachycardia
  - Hyperpnea
256. To differentiate between supraventricular tachycardia and ventricular tachycardia of aberrant conduction all the following points support the latter except
- Wide QRS >0.16 secs
  - Carotid massage causes a 2:1 block
  - Oesophageal leads show A-V dissociation
257. Linked angina means..
- Tietz syndrome
  - Viral pericarditis
  - Variant angina
  - Angina caused by myocardial ischaemia due to Gastrointestinal disturbances.
258. Any visible edema of both lower extremities each preceded by weight gain of
- 0.5-1kg
  - 1-2kg
  - 3-5kg
  - 5-7kg
259. In pheochromocytoma there is increased level of
- Serum HMA
  - Serum bradykinin

- c. Urinary VMA
- d. All of the above

**260. Pulsatile exophthalmos is seen in**

- a. Severe AR
- b. SEVERE TR
- c. TR
- d. MR

**261. Osteogenesis imperfecta may be associated with all except:**

- a. Aortic dialation
- b. AR
- c. MVP
- d. PR

**262. Kussamaul's sign is**

- a. Paradoxical rise in height of JVP
- b. Paradoxical decrease in height of the JVP
- c. Seen in AS
- d. Typically occurs in cardiac tamponade

**263. W shaped JVP is seen in**

- a. Constrictive pericarditis
- b. RCM
- c. DCM
- d. HOCM

**264. Dicrotic notch in normal pulse indicated**

- a. Opening of mitral valve
- b. Opening of aortic valve
- c. Closure of MV
- d. Closire of AV

**265. Pulsustardus means**

- a. Late peaking
- b. Slow rising
- c. Reduced peak
- d. Small amplitude

**266. Visible pulsation of the retinal artery is known as**

- a. Hill's sign
- b. Duoroziez's sign
- c. Traube's sign
- d. Beckers sign

**267. Urokinase and streptokinase are contraindicated in**

- a. Malignancy
- b. A-V fistula
- c. Pulmonary embolism
- d. Thrombophlebitis

**268. Loud S1 is seen in all except**

- a. Short PR interval
- b. AF
- c. MS
- d. Rapid heart rate

**269. Reverse splitting of s2 is seen in**

- a. RBBB
- b. LBBB
- c. LV Placed beats
- d. Lv ectopic beats

**270. Diastasis phase accounts for -----% of ventricular filling**

- a. 80%
- b. 70%
- c. 60%
- d. <5%

**271. Which are the values of Troponin T that are prognostically significant?**

- a.  $\geq$  to 0.05 ng/ml
- b.  $\geq$  to 0.1 ng/ml
- c.  $\geq$  to 0.001 ng/ml
- d.  $\geq$  to 0.01 ng/ml

**272. Most consistant phase of pericardial rub is**

- a. Systolic phase
- b. Presystolic
- c. Mid diastolic
- d. All of the above

**273. The most common cause of secondary hypertension in children is**

- a. Renal artery stenosis
- b. Adrenal tumors
- c. Renal disease
- d. Coarctation of aorta

**274. The duration of the depolarisation of the heart from the SA node to the AV node is reflected on the ECG by**

- a. QT interval
- b. PR interval
- c. RS interval
- d. RR interval

**275. Digoxin toxicity can be recognized when there is**

- a. QT interval is shortened
- b. Ventricular bigeminy
- c. Atrial flutter
- d. Mobitz II degree heart block

**276. Classical S1, Q3, T3 PATTERN occurs in----- % cases of acute PTE**

- a. 5%
- b. 10%
- c. 20%
- d. 30%

**277. Preferred antihypertensive in patients of Benign Prostatic Hypertrophy is**

- a. ACE Inhibitors
- b. Ca channel Blockers
- c. Alpha Blockers
- d. Beta Blockers

**278. Ductus Venosus is a low resistance bypass between**

- a. Pulmonary vein & IVC
- b. Portal Vein & IVC
- c. Hepatic Vein & IVC
- d. None

**279. Fetal cardiac activity can be earliest detected by:**

- a. 4week
- b. 6 week
- c. 5 week
- d. 10 week

280. **PulsusParadoxus is commonly seen in:**
- Constrictive pericarditis
  - Cardiac tamponade
  - Restrictive cardiomyopathy
  - Risperidone
281. **Most common congenital heart disease in adults**
- ASD
  - Tetralogy of fallot
  - VSD
  - bicuspid Aortic valve
282. **150/100 mm Hg falls in which category of Hypertension as per JNC7**
- stage-1
  - Stage-II
  - stage-III
  - Stage of pre\_Hypertension
283. **What does the abbreviation CAVHD stand for?**
- Coronary atrioventricular heart disease
  - Cavernous atrioventricularhemopoetic disease
  - Continuous Arterio Venous Hemo Dialysis
  - Calcified aortic venous heterozygous disease
284. **The left to right shunt is seen in all of the following except**
- PDA
  - VSD
  - ASD
  - TGA
285. **Digoxin is used in which of the following conditions**
- Atrial ectopics
  - Flutter with 2:1 block
  - Ventricular tachyarrhythmia
  - Ventricular bigeminy
286. **The duration of the depolarisation of the heart from the SA node to the AV node is reflected on the ECG by**
- QT interval
  - PR interval
  - RS interval
  - RR interval
287. **The most common cause of secondary hypertension in children is**
- Renal artery stenosis
  - Adrenal tumors
  - Renal disease
  - Coarctation of aorta
288. **Which are the values of Troponin T that are prognostically significant?**
- $\geq 0.05$  ng/ml
  - $\geq 0.1$  ng/ml
  - $\geq 0.001$  ng/ml
  - $\geq 0.01$  ng/ml
289. **Urokinase and streptokinase are contraindicated in**
- Malignancy
  - A-V fistula
  - Pulmonary embolism
  - Thrombophlebitis
290. **In pheochromocytoma there is increased level of**
- Serum HMA
  - Serum bradykinin
  - Urinary VMA
  - All of the above
291. **An asymptomatic 44 year old male was detected with an abnormality on cardiac examination. His ECG showed a Left Bundle Branch. His 2D Echo showed an Ejection fraction of 55% with no regional wall motion abnormality and no significant valvular pathology. The abnormality detected on cardiac examination was:**
- Wide Splitting of the S1
  - Reverse Splitting of the S2
  - Mid diastolic murmur at apex
  - Continuous murmur in the infraclavicular area
292. **A 64 year old female was diagnosed with Severe Mitral stenosis with moderate mitral regurgitation with LV Systolic dysfunction. Her ECG showed sinus rhythm with a PR Interval of 220 msec. On cardiac examination her first heart sound would be:**
- Loud
  - Soft
  - Variable intensity
  - Wide Split
293. **A 30 years old female with Primary Pulmonary Hypertension had a 2D Echo with normal LV and RV systolic function and an estimated PA Systolic pressure of 85 mmHg. This would be reflected on clinical examination as which of the following findings?**
- Widely Split S2 with Soft P2
  - Narrowly Split S2 with Soft P2
  - Widely Split S2 with loud P2
  - Narrowly split S2 with Loud P2
294. **An asymptomatic 11 year old male child was found to have a wide and fixed split of the second heart sound on cardiac examination. He had no murmurs and no other adventitious sounds. His ECG and Chest X Ray were within normal limits. What would be the next most appropriate investigation?**
- Reassurance. No further investigations required.
  - 2D Echocardiography
  - Cardiac MRI
  - ASO Titres
295. **All the following sounds occur during diastolic phase of the cardiac cycle EXCEPT**
- S4
  - Opening Snap
  - Aortic Ejection Click
  - Pericardial Knock
296. **Closure of the Mitral and Tricuspid Valve are following by which phase of the cardiac cycle?**
- Iso-volumetric Contraction
  - Ejection
  - Iso-volumetric Relaxation
  - Diasthesis
297. **All the following regarding the Third Heart Sound are true EXCEPT**
- Occurs 120 – 200msec after the second heart sound
  - Occurs due to early rapid filling phase

- c. Can be heard in VSD and PDA
- d. Occurs normally in elderly patients

298. **The Fourth Heart Sound can be heard in**

- a. Presence of a Non-compliant left ventricle
- b. Atrial fibrillation
- c. Severe Mitral Stenosis
- d. Chronic Mitral Regurgitation

299. **Which Heart Sound corresponds with the 'a' wave of the JVP?**

- a. S1
- b. S2
- c. S3
- d. S4

300. **A 55 year old lady with symptoms of exertional palpitations, insomnia, irritability and heat intolerance was diagnosed with hyperthyroidism. The following would be expected findings on cardiovascular system examination EXCEPT**

- a. Atrial fibrillation
- b. Wide Pulse Pressure
- c. Soft S1
- d. Means Lerman Scratch

301. **A 55 year old male with history of Exertional angina and a single episode of syncope was found to have a Constant Systolic Ejection Click at the Aortic Area, a soft A2, S4 and an Ejection Systolic Murmur with a delayed systolic peak. His diagnosis is**

- a. Bi-cuspid Aortic Valve with Severe Aortic Stenosis
- b. Degenerative Calcified Severe Aortic Stenosis
- c. Hypertrophic Cardiomyopathy with a Severe LV outflow tract obstruction
- d. Sub Valvular Membrane with severe aortic stenosis

302. **A 22 year old patient with Marfans syndrome can have the following findings on cardiac examination EXCEPT**

- a. Waterhammer Pulse
- b. S4
- c. Pulsations in the Suprasternal notch
- d. Early diastolic murmur in aortic area

303. **A 46 year old male was diagnosed with Rheumatic Heart disease with Mild Mitral Stenosis 8 years ago. He has gradual worsening of Dyspnea on exertion since 6 months. Which of the following findings indicate increased severity of Mitral Stenosis**

- a. Loud S1
- b. Intensity of Opening Snap
- c. Wide A2-OS interval
- d. Length of Mid Diastolic Murmur

304. **All the following about Opening Snap are false EXCEPT**

- a. Systolic sound occurring after S1
- b. Indicates pliability of the mitral valve
- c. A2 – OS interval correlates directly with severity of mitral stenosis
- d. Often heard in Calcific Mitral stenosis

305. **The following sequence of diastolic sounds according to the timing of their occurrence is CORRECT:**

- a. A2-P2-OS-S3-S4
- b. P2-A2-OS-S3-S4
- c. A2-P2-S3-S4-OS
- d. A2-P2-S3-OS-S4

306. **A 60 year old Diabetic and hypertensive male presented to the casualty with severe chest pain radiating to the left arm associated with severe breathlessness and orthopnoea. His ECG showed an evolving anterior wall myocardial infarction. All of the following finding on cardiac auscultation would indicate a complication of a Myocardial Infarction EXCEPT**

- a. S3-S4 gallop
- b. Pericardial Rub
- c. Early diastolic Murmur at the aortic area
- d. Pan systolic murmur at the apex

307. **Which of the following findings would help to differentiate Hypertrophic Cardiomyopathy from Valvular Aortic Stenosis?**

- a. Bisferians Pulse
- b. Opening Snap
- c. Ejection Systolic Murmur with a delayed peak
- d. S4

308. **All of the following findings would help to differentiate an Austin Flint Murmur of Aortic Regurgitation from a Mid-diastolic Murmur of Mitral Stenosis EXCEPT**

- a. Wide Pulse Pressure
- b. S3
- c. JVP
- d. Location of the Apex Impulse

309. **All the following indicate Severity of Mitral Regurgitation EXCEPT**

- a. Soft S1
- b. S3
- c. Mid Diastolic Murmur
- d. Systolic Thrill

310. **A 26 year old male was admitted with Infective Endocarditis with Severe Aortic Regurgitation. His cardiac auscultation revealed all the following murmurs EXCEPT**

- a. Ejection systolic murmur at the aortic area radiating to the Carotids
- b. Short Early Diastolic Murmur at the aortic area
- c. Mid Diastolic Murmur at the apex
- d. Early Systolic murmur at the apex

311. **A 26 year old male was diagnosed with Hypertrophic Cardiomyopathy. His cardiac examination revealed one of the following findings:**

- a. Pulsus Alternans
- b. Aortic Ejection Click
- c. Mid Systolic Murmur increasing in standing position
- d. Mid Systolic Murmur decreasing in Phase II of Valsalvas manouver.

312. **The following combination of Murmur and Cardiac Pathology is INCORRECT**

- a. Gibsons Murmur – Patent Ductus Arteriosus
- b. Rytands Murmur – Severe Aortic Regurgitation
- c. Carey Coumbs murmur – Rheumatic Fever
- d. Graham Steele's Murmur – Hypertensive Pulmonary Regurgitation

313. **The following are causes of Continuous murmurs except:**

- a. Aortopulmonary Window
- b. Rupture of Sinus of Valvsalva Aneurysm
- c. Post Bidirectional Glenns Shunt
- d. Coronary AV Fistula

314. A 7 year old boy presented with fatigue and reduced activity since 1 year. On examination, he had pan-digital clubbing and central cyanosis. He was diagnosed with Tetralogy of Fallot. Which of the following findings would correlate with the diagnosis of TOF ?
- Narrowly Split Second Heart Sound
  - Loud P2
  - Pan systolic murmur
  - Continuous murmurs at the back and axilla
315. Which of the following regarding response to Strain phase of Valsalva Manouever is INCORRECT ?
- HOCM Murmur – increases in intensity
  - Mitral Valve Prolapse – Click occurs later and Murmur is louder
  - Aortic Stenosis Murmur – decreases in intensity
  - Mitral Stenosis Murmur – decreases in intensity
316. The normal apical impulse is characterized by all except
- Lowermost and outermost point of maximal impulse in late systole
  - Located in 4th or 5th intercostal space inside the midclavicular line within 10 cm from midsternal line
  - Palpable area of 2-2.5 sq cm and localized to one intercostal space
  - Gentle non sustained tap
317. Left parasternal pulsations are palpable in all except
- Aortic regurgitation
  - Tricuspid regurgitation
  - Mitral regurgitation
  - Pulmonary stenosis
318. The following may be associated with a heaving apex beat
- Seen in volume overload states
  - Lasts <50% of systole
  - There is increased amplitude and duration of LV ejection
  - May be seen in thin chest individuals
319. Palpable S4 is seen in all except
- Acute mitral regurgitation
  - Acute aortic regurgitation
  - Aortic stenosis
  - Chronic severe mitral regurgitation
320. Rotch's sign may be seen in
- Constrictive Pericarditis
  - Acute cardiac tamponade
  - Massive pericardial effusion
  - Restrictive cardiomyopathy
321. All cause clubbing except
- TAPVC
  - Bronchogenic carcinoma
  - Ulcerative colitis
  - ASD
322. A 45 year old man presented with chest discomfort, progressively increasing breathlessness over the past two years which has progressed from NYHA class I to III with episodes of PND. Recently he has noticed bilateral pitting pedal edema. All could be the differential diagnosis except
- Dilated cardiomyopathy with heart failure
  - Left sided valvular heart disease
  - Coronary artery disease with LV dysfunction
  - ILD with pulmonary artery hypertension.
323. Peripheral edema may be seen in
- Aortic stenosis
  - Constrictive pericarditis
  - Pericardial effusion
  - Atrial septal defect
324. Reverse differential cyanosis may be seen in
- PDA with PAH and reversal of shunt
  - Coarctation of aorta with interrupted aortic arch with PDA having right to left shunt
  - TGA with preductal narrowing, PAH and reverse flow through PDA
  - Double outlet right ventricle
325. Central cyanosis may be due to
- TOF with multiple aorto pulmonary collaterals
  - Corrected transposition of great arteries
  - Congestive heart failure
  - Truncus arteriosus
326. The closure of the aortic valve corresponds to which phase of the pulse wave
- Percussion wave
  - Anacrotic notch
  - Tidal wave
  - Dicrotic notch
327. The pulse shown in the figure is characteristic of

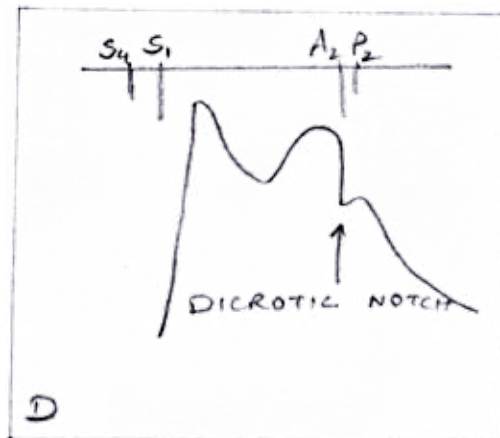


Figure 2

- Hypertrophic obstructive cardiomyopathy
  - Severe aortic stenosis
  - Severe aortic regurgitation
  - Cardiomyopathy with severe LV dysfunction
328. Pulsus alternans is seen in
- Massive pericardial effusion
  - Dilated cardiomyopathy with severe left ventricular dysfunction
  - Moderate aortic regurgitation with severe aortic stenosis
  - Constrictive pericarditis



**1140 329. Pulsus paradoxus may be seen in**

- a. Restrictive cardiomyopathy
- b. Pericardial tamponade
- c. Primary pulmonary artery hypertension
- d. Hypertrophic obstructive cardiomyopathy

**330. A first year MBBS student has just learnt the art of BP measurement. His professor will give him all the instructions except**

- a. Look for orthostatic hypotension in old age individuals
- b. If thigh cuff is not available, arm cuff may be tied at the level of ankle for measurement of lower limb BP
- c. The systolic pressure is estimated by the palpatory method and diastolic pressure by the auscultatory method
- d. During BP measurement, the BP apparatus should be at the level of the heart

**331. An intern is posted in the medicine ward. He has been asked to monitor a patient with sepsis. His professor has asked him to inform him if mean pressure is <70 mm Hg or there is urine output <30ml/hour. How will he calculate the mean pressure.**

- a. Mean BP = Systolic BP - Diastolic BP
- b. Mean BP = Diastolic BP + 1/3 pulse pressure
- c. Mean BP = Diastolic BP + 1/3 systolic BP
- d. Mean BP = Systolic BP/2 + Diastolic BP/2

**332. A medicine resident is examining the JVP of a patient in his final examination. JVP is best examined in**

- a. Reclining at 45 degree
- b. Supine
- c. Sitting
- d. Any position where the peak of the venous column is well identified

**333. The JVP is best timed with cardiac cycle by which of the following**

- a. A wave is visible just before the carotid pulse
- b. A wave coincides with S4
- c. X descent is between S1 and S2, X' is simultaneous with radial pulse
- d. V wave peaks after S2

**334. The X' descent is due to**

- a. Atrial relaxation
- b. Downward pull of tricuspid valve by contracting RV
- c. Impact of carotid artery and upward bulging of closed tricuspid valve
- d. RA emptying when tricuspid valve opens

**335. Cannon A waves may be seen in**

- a. Isorhythmic AV dissociation
- b. Acute pulmonary embolism
- c. Severe Tricuspid stenosis
- d. Hypertrophic obstructive cardiomyopathy

**336. A 35 year old female is a known case of rheumatic heart disease with severe mitral stenosis. She has been complaining of progressively increase in breathlessness since the last 2 years. Presently she has noticed symptoms of PND. The reason for the PND may be all except**

- a. Pulmonary arterial hypertension
- b. Pulmonary venous hypertension
- c. Decreased sympathetic drive during sleep
- d. Increased venous return during supine position

**337. A 60 years old gentleman complaints of an episode of syncope. He was diagnosed as bicuspid aortic valve with severe aortic stenosis. He has been advised valve replacement. What could be the probable cause of syncope in him**

- a. Atrial fibrillation
- b. Exertion induced
- c. Myocardial ischemia
- d. All of the above

**338. A 23 year old boy is a known case of Marfan's syndrome. He presents with sudden onset breathlessness and is suspected of having acute aortic regurgitation. His clinical manifestations may include**

- a. Normal pulse pressure
- b. Positive Hill's sign
- c. Water hammer pulse
- d. Anacrotic pulse

**339. A 19 year old female presents with swelling of the feet. She has atrial fibrillation. Her JVP shows an attenuated X descent. What is her differential diagnosis**

- a. Severe mitral stenosis
- b. Severe mitral stenosis with moderate mitral regurgitation
- c. Severe pulmonary regurgitation secondary to pulmonary artery hypertension
- d. Severe TR

**340. A prominent X and prominent Y descent may be seen in**

- a. Constrictive pericarditis
- b. Restrictive cardiomyopathy
- c. Dilated cardiomyopathy with heart failure
- d. HOCM

1. d: This is a typical cause of stroke in a young person due to prolonged immobility. Deep vein thrombosis with patent foramen ovale will cause paradoxical embolism and stroke.
2. c: Atrial myxomas are more often on the left. Though benign, they can occlude the mitral valve and produce sudden loss of cardiac output. They may embolize small portions of themselves or thrombus formed over their surface.
3. b: The uraemia leads to exudation of fibrin onto the epicardial and pericardial surfaces. Haemorrhagic pericarditis is more typical of tuberculosis or metastatic tumour. Serous pericarditis is more typical of collagen vascular diseases.
4. d
5. e: The macrolides are associated with a prolongation of the QT interval. Other antimicrobials associated with prolonged QT include quinine, levofloxacin.
6. e
7. b
8. c
9. a: There is a single sound in Fallot's because of an absent P2. Aortic stenosis leads to reversed splitting (also seen with LBBB and ventricular pacemaker). In RBBB there is wide splitting of S2 but it is not fixed.
10. d: The suggestion here is that this man has coronary artery disease with an impending myocardial infarction. Infarction of the LAD would cause necrosis of the left ventricle. Thrombus may form on an area of dyskinetic ventricle. Therefore he is most at risk of embolus of thrombus from the LV.
11. b: Many drugs can cause a prolonged QT interval. more
12. c
13. e
14. a
15. b
16. a
17. a: The bioprosthesis has the advantage of not requiring anticoagulation, but it does not wear well with time, and typically must be replaced within 5 to 10 years
18. b
19. d
20. e
21. c
22. a
23. d
24. d
25. d
26. a
27. d
28. d
29. b
30. e
31. e
32. d
33. a
34. e
35. e
36. c: This patient has NYHA stage II heart failure. Studies such as CIBISII and MERIT HF reveal that beta blockers significantly reduce morbidity and mortality in heart failure.
37. d
38. d: Acanthocytes are seen in abetalipoproteinaemia. Retinitis pigmentosa is seen in abetalipoproteinaemia. Mental retardation is not present but motor abnormalities and neurodegenerative are seen.
39. d: Quaternary syphilis involves the cardiovascular system commonly in form of ascending aortic aneurysm and aortic regurgitation. Diphtheria, coxsackievirus, Chagas disease and toxoplasmosis are all associated with myocarditis.
40. b
41. b
42. d
43. c
44. c
45. e
46. c
47. e
48. b
49. b: The results show normal T4, low T3 with elevated TSH. These results are typical of amiodarone induced hypothyroidism which inhibits the peripheral conversion of T4 to T3.
50. e: This lady has Chronic Obstructive Airways disease and subsequent Cor Pulmonale leading to right heart failure. Nonbacterial thrombotic endocarditis is a condition seen in frail ill individuals.
51. c
52. c
53. d: Omeprazole is associated with gynecomastia.
54. e
55. b
56. a
57. e

59. a

60. b

61. e

62. a: Bicuspid aortic valve is perhaps the most common form of congenital heart disease in adults. Bicuspid valves have a propensity to wear out and calcify with aging. Bicuspid aortic valve tends to be a sporadic.

63. c

64. c

65. b

66. b

67. b

68. e: The history is typical of aortic dissection. All the others could cause sudden collapse but not with acute chest pain radiating to the back in the presence of a recent normal exercise test. Acute MI is possible but not the most likely.

69. d: The Austin Flint murmur is a low frequency mid/late diastolic murmur which may show presystolic accentuation which is virtually indistinguishable from that of mitral stenosis. There is no correlation between presence of murmur and severity of AR, or aetiology. The first heart sound is normal but in severe cases, it may be absent.

70. d: Patients with HCM are at increased risk of sudden cardiac death due to VF/VT. Implantable Cardio Defibrillators (ICD) are superior to Amiodarone or Beta Blockers for preventing this. Reducing outflow tract obstruction with myectomy or Alcohol Septal Ablation does not reduce the risk of SCD.

71. c

72. e

73. d

74. b

75. a: Ischaemia, typically in hypotensive hospitalized patients, is the most frequent antecedent to acute tubular necrosis. Blood pressure should be maintained in cardiogenic shock with fluids and / or inotropic agents.

76. a: Cisapride has been withdrawn due to the problem of prolonged QT interval and torsades de pointe. Prolonged QT is defined as greater than 0.45s. Other agents include amitriptyline and phenothiazines yet metoclopramide and domperidone are not associated.

77. b

78. e

79. a

80. e: WPW can be associated with negative delta waves in II, III and aVF. The long term management of choice is ablation of the accessory pathway.

81. a

82. a

83. b

84. e

85. e

86. e

87. a

88. c

89. e

90. a: This man has alcoholic liver cirrhosis with ascites. The cardiomyopathy of alcoholism is a dilated or congestive form.

91. a

92. b

93. c

94. b

95. d

96. c

97. b

98. b

99. e

100. d

101. e

102. a

103. e

104. e

105. d: Selenium deficiency is one of the reversible causes of dilated cardiomyopathy.

106. e

107. e

108. b

109. d

110. a

111. a

112. a

113. a: This MI is likely to be in the LAD and represents an anterior MI.

114. a: Although troponin is highly sensitive and specific it remains elevated for at least one week after infarction. Similarly LDH will be present for approximately one week after infarction. After myocardial infarction, CKMB levels become elevated within 3 to 8 hours, peak within 9 to 30 hours, and return to normal after 48 to 72 hours. Although myoglobin has a short half life and rises quickly after an MI and is cleared after an MI, it is not specific enough for diagnostic use.

115. a

116. d

117. d

118. d

|        |        |        |        |        |
|--------|--------|--------|--------|--------|
| 119. d | 159. a | 199. c | 239. a | 279. c |
| 120. c | 160. b | 200. a | 240. d | 280. b |
| 121. a | 161. b | 201. b | 241. e | 281. d |
| 122. d | 162. c | 202. b | 242. c | 282. b |
| 123. d | 163. a | 203. c | 243. c | 283. c |
| 124. c | 164. d | 204. a | 244. c | 284. d |
| 125. b | 165. a | 205. b | 245. a | 285. b |
| 126. a | 166. a | 206. c | 246. c | 286. a |
| 127. e | 167. a | 207. d | 247. a | 287. c |
| 128. d | 168. e | 208. a | 248. e | 288. d |
| 129. d | 169. a | 209. a | 249. d | 289. a |
| 130. c | 170. a | 210. a | 250. c | 290. c |
| 131. d | 171. e | 211. a | 251. e | 291. b |
| 132. c | 172. b | 212. c | 252. a | 292. b |
| 133. e | 173. e | 213. d | 253. b | 293. d |
| 134. b | 174. b | 214. d | 254. b | 294. b |
| 135. a | 175. a | 215. b | 255. b | 295. c |
| 136. b | 176. c | 216. e | 256. b | 296. a |
| 137. d | 177. c | 217. c | 257. d | 297. d |
| 138. b | 178. d | 218. e | 258. c | 298. d |
| 139. a | 179. d | 219. a | 259. c | 299. d |
| 140. b | 180. d | 220. c | 260. b | 300. c |
| 141. a | 181. d | 221. d | 261. b | 301. a |
| 142. a | 182. d | 222. b | 262. a | 302. b |
| 143. b | 183. d | 223. d | 263. a | 303. d |
| 144. c | 184. a | 224. a | 264. d | 304. b |
| 145. e | 185. d | 225. d | 265. b | 305. a |
| 146. b | 186. b | 226. c | 266. d | 306. c |
| 147. b | 187. b | 227. b | 267. a | 307. a |
| 148. d | 188. c | 228. b | 268. b | 308. c |
| 149. c | 189. c | 229. b | 269. b | 309. a |
| 150. c | 190. d | 230. b | 270. d | 310. d |
| 151. e | 191. c | 231. d | 271. d | 311. c |
| 152. c | 192. d | 232. c | 272. a | 312. b |
| 153. c | 193. d | 233. d | 273. c | 313. c |
| 154. b | 194. a | 234. a | 274. a | 314. d |
| 155. c | 195. a | 235. a | 275. b | 315. b |
| 156. b | 196. a | 236. c | 276. b |        |
| 157. d | 197. b | 237. a | 277. c |        |
| 158. b | 198. c | 238. d | 278. b |        |

## 291 &amp; 292. First Heart Sound

| Loud S1   | Soft S1   | Variable S1          |
|---|---|----------------------|
| Normal in children                                  | Mitral / Tricuspid Regurgitation                  | Atrial fibrillation  |
| Sinus tachycardia                                   | Mitral valve Prolapse                             | Complete heart block |
| Mitral Stenosis                                     | Calcified Mitral stenosis                         | AV Dissociation      |
| LA Myxoma   | Acute Myocardial infarction                       |                      |
| Exercise  | Cardiomyopathy,                                   |                      |
| Hyperdynamic State                                  | LV Aneurysm                                       |                      |
| Short PR Interval                                   | Myocarditis                                       |                      |
|   | LBBB  |                      |
| <b>LOUD T1</b>                                      | Thick chest wall, Obesity                         |                      |
| Tricuspid stenosis                                  | Pericardial effusion                              |                      |
| RA Myxoma   | Emphysema   |                      |
| Esbteins anomaly                                    |   |                      |
| Atrial septal defect                                |   |                      |
| Total anomalous pulmonary venous connection (TAPVC) |   |                      |
| <b>Wide Split S1 (Delayed T1)</b>                   | <b>Paradoxical/ Reverse Split S1 (Delayed S1)</b> |                      |
| <b>Electrical :</b>                                 | <b>Electrical :</b>                               |                      |
| RBBB  | LBBB  |                      |
| LV Pacing, LV Ectopics                              | RV Pacing, RV Ectopics                            |                      |
| Idioventricular Rhythm from LV                      | Idioventricular Rhythm from RV                    |                      |
| <b>Mechanical</b>                                   | <b>Mechanical</b>                                 |                      |
| Ebsteins anomaly                                    | Mitral Stenosis                                   |                      |
| Tricuspid stenosis                                  | LA Myxoma   |                      |
| RA Myxoma   |   |                      |

## 293 &amp; 294. Second Heart Sound

Splitting of S2

Wide Split S2 may be due to delayed P2 or early A2.

A. Delayed P2

- Electrical:-
  - o RBBB
  - o LV Pacing/ LV Ectopics
- Mechanical:-
  - o Pulmonary Stenosis
  - o Acute Pulmonary Embolism
- Increased Hangout interval Interval:-
  - o ASD

B. Early A2

- MR
  - VSD
- C. Others:-
- Normal in Children
  - Straight back Syndrome
  - Pectus Excavation
  - Ebsteins anomaly, TAPVC, Common Atrium

Wide Fixed Split S2:-

- ASD,
- TAPVC, Common Atrium
- Acute Pulmonary Embolism
- Severe RV Failure

Reverse Split S2 may be due to delayed A2 or early P2

A. Delayed A2

- Electrical:-
  - o LBBB
  - o RV Ectopic/RV Pacing
- Mechanical:-
  - o LVOT Obstruction (Aortic Stenosis/Coarctation of Aorta)
  - o Hypertension
  - o LV Dysfunction (IHD)

B. Early P2

- WPW Type IB
- RA Myxoma,
- Tricuspid Regurgitation

Single S2

a. Absent/Undetectable P2

- Age>60
- Obesity, Thick Chest, Emphysema
- Vascular Pulmonary Stenosis
- Severe Aortic Stenosis (murmur masks P2)
- Tetralogy of Fallot
- Pulmonary Atresia

b. Absent / Undetectable A2

- Vascular AS
- Aortic Atresia
- Severe Pulmonary Stenosis (Syst. murmur mask A2)
- Severe Pulmonary Hypertension (retrograde masking)

| Loud A2                            | Soft A2                         |
|------------------------------------|---------------------------------|
| Hyperkinetic States                | Age, Aortic Sclerosis           |
| Systemic Hypertension              | Vascular Aortic stenosis        |
| Aortic Aneurysm                    | Vascular Aortic regurgitation   |
| Aortic Root Pathology (Syphilis)   |                                 |
| Cong Bicuspid AV                   |                                 |
| Pulmonary Atresia                  |                                 |
| Loud P2                            | Soft P2                         |
| Hyperkinetic States                | Vascular Pulmonary stenosis     |
| Pulmonary Hypertension             | Dysplastic Pulmonary Valve      |
| ASD (even in absence of PH)        | Obesity, Thick Chest, Emphysema |
| Thin Chest, Straight Back Syndrome |                                 |

Wide & Fixed S2 in ASD

1. Wide Split S2 Wide split occurs due to delayed P2

Inspiration leads to a increased negative intrathoracic pressure that in turn leads increased venous return and increased RV Filling . This leads to

- Increased RV Ejection Time
  - Increased right hangout interval
  - Right Bundle Branch Block
2. Fixed Split S2
- A. Phasic Changes in Venous Return
- Inspiration leads to an increased venous return and no left to right shunt across the ASD.
  - Expiration leads to a reduced venous return and a increase in the left to right shunt across the ASD. Therefore there is an increased RV filling in both expiration & inspiration that produces a fixed split.
- B. Increased Pulmonary Capacitance due to ADS leads to an increased pulmonary blood flow. There is no further increase in pulmonary blood flow during inspiration leading to a fixed split.

## 295. Diastolic Heart Sounds

Sequences of Diastolic Events:

A2- P2- Opening Snap- Pericardial Knock – Tumour Plop - S3-S4

Timing of Diastolic Sounds in Relation to the Second Heart Sound:

A2-P2

- Inspiration: 40-50 msec
- Expiration: <30 msec

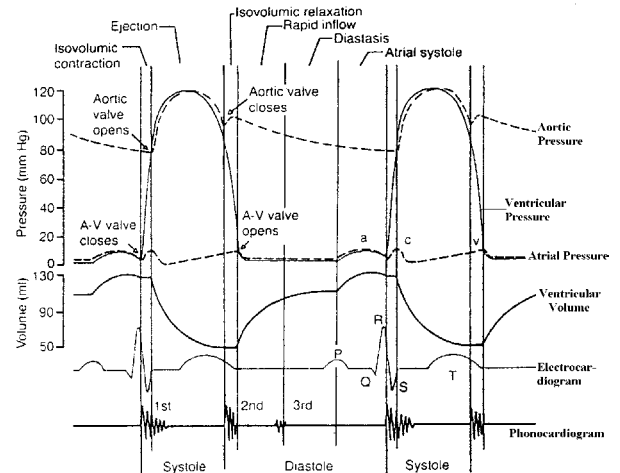
A2-Opening Snap: 30-150 msec

A2 – Pericardial Knock: 100-120 msec

A2 - S3:

- Physiological: 120-200 msec
- Pathological: 140-160 msec

## 296. Cardiac Cycle



Closure of the AV Valves (mitral and tricuspid valves) heralds the end of diastole. At this stage, all the four valves – mitral, tricuspid, aortic and pulmonary valves are closed. The ventricular systole has begun without the change in volume of the ventricles. This is the phase of Isovolumetric Contraction.

## 297. Third Heart Sound

Characteristics:

- Low Pitched, Mid Diastolic Sound
- Early Rapid Ventricular Filling Phase
- Also called S3 Gallop, Protodiastolic Gallop, Ventricular Diastolic Gallop
- Co- insides with- Y Decent of JVP

Timing:

- PATHOLOGICAL: 140-160msec after A2
- PHYSIOLOGICAL: 20-200 msec after A2

Causes of S3

- PHYSIOLOGICAL:
  - o Children
  - o Young Adults (40+ <50)
  - o Pregnancy
  - o Anxiety
  - o Exercise
- PATHOLOGICAL:
  - o Hyperkinetic Status
  - o MR, TR (RVS3)
  - o VSD, PDA, ASD (RVS3)
  - o Ischemic heart disease
  - o Dilated Cardiomyopathy (DCM)

## 298. Fourth Heart Sound

Characteristics:

- Low frequency, Late Diastolic Sound

- Last Rapid Filling Phase of Diastolic i.e. Atrial Contraction
- Presystolic Gallop, Atrial Diastolic Gallop
- ECG= 70 msec after P wave
- JVP= Just after A wave

Causes:

- Physiological:
  - o Elderly >60 years
- PATHOLOGICAL:
  - o Hyperkinetic States,
  - o AV Fistula
  - o Acute MR, TR or AR
  - o LVOT Obstruction- Aortic Stenosis, HOCM
  - o Systemic Hypertension
  - o RVOT Obstruction- P.S.
  - o Pulmonary Hypertension
  - o Pulmonary Embolism
  - o Ischemic heart disease
  - o LV Aneurysm
  - o Heart blocks

299. See 206 and 208 for explanation

### 300. HYPERTHYROIDISM AND HEART

Hyperthyroidism can produce the following cardiovascular effects

- o Palpitations, Angina, Exercise intolerance, Exertional dyspnoea
- o Peripheral edema
- o Hyperdynamic precordium, wide pulse pressure
- o Atrial fibrillation
- o Cardiac Hypertrophy
- o Systolic Hypertension
- o Congestive cardiac failure

The Means–Lerman scratch is a rare murmur found in patients with hyperthyroidism. It is a mid-systolic scratching sound best heard over the upper part of the sternum or second left intercostal space at the end of expiration.

### 301. Aortic Click

Characteristics

- S1-EC= 50 msec
- Coincides with ANACROTIC NOTCH on the upstroke of aortic pressure Trace
- Indicated Mobile AV leaflets
- Heard at apex or base
- Constant click: No respiratory variation

- Localizes the LVOT obstruction to valvular level; Bicuspid Aortic Valvular Stenosis.

Symptoms of syncope and examination findings of soft A2, S4 and an Ejection Systolic Murmur with a delayed systolic peak are found in any severe left ventricular outflow tract obstruction.

The constant click localizes the LVOT obstruction to the valvular level; to a bicuspid aortic valvular stenosis.

In Degenerative Aortic Stenosis the valve leaflets are not mobile to produce a click. In Hypertrophic cardiomyopathy or sub-valvular membrane aortic click is not heard.

### 302. Cardiac Manifestations of Marfans Syndrome

Cardiac Manifestations of Marfans syndrome:

- Aortic Regurgitation
- Aortic Aneurysm
- Aortic Dissection
- Mitral Valve Prolapse

In Marfans syndrome, a waterhammer pulse and an early diastolic murmur in aortic area can be seen due to aortic regurgitation. Pulsations in the suprasternal notch can be a sign of an aortic aneurysm.

### 303. AUSCULTATION IN MITRAL STENOSIS

Characteristic findings on auscultation

- Loud S1
- Absence of S3 or S4
- Opening snap
- Low pitched rumbling mid-diastolic murmur with presystolic accentuation

In mitral stenosis, the loudness of the S1 and intensity of the opening snap correlate with the mobility and pliability of the mitral valve. Calcific mitral stenosis will usually have a soft S1 and absent opening snap.

The A2-OS interval is inversely proportionate to the severity of mitral stenosis. (Refer to explanation in Q14)

The length of the mid diastolic murmur indicates the duration of time for which the gradient across the mitral valve is maintained.

As the severity increases, the longer is the gradient sustained and the longer is the mid-diastolic murmur.

### 304. OPENING SNAP

Characteristics

- High Frequency Sounds
- Early Diastolic Sound - A2-OS= 30-150 msec
- Indicates pliable mitral valve
- Intensity of OS parallels Loudness of S1

Pre-Requisite:

- AV Valves Leaflets Thickened But MOBILE
- LA Pressure high
- Velocity across AV Valves High- Rapid excursion of leaflets

Causes:

- Mitral Stenosis
- Rare Causes
  - o Tricuspid stenosis
  - o MR, TR
  - o VSD,PDA, ASD, Ebsteins
  - o HOCM

A2-OS Interval: As the severity of mitral stenosis increases, the opening snap occurs earlier in diastole. As the severity of MS increases, the LA pressure is higher and thus the earlier does the LA pressure increase above the LV diastolic pressure to produce opening of the mitral valve and the opening snap.

Therefore, the A2-OS interval is inversely proportionate to the severity of the mitral stenosis.

Absent OS in MS:

- o Mild MS
- o Calcified Immobile MV
- o Associated Severe MR
- o Associated Severe AR
- o Associated Coronary artery disease/ LV Dysfunction

### 305. Diastolic Heart Sounds: Refer to explanation of Q5

### 306. Auscultation during Acute Myocardial Infarction

During an acute myocardial infarction, auscultation can assist in determining certain complications.

- a. A S3-S4 gallop indicates Congestive cardiac failure.
- b. A Pericardial Rub indicates Pericarditis
- c. Pan systolic murmur at the apex indicates a mitral regurgitation due to papillary muscle dysfunction or rupture. A pan systolic murmur in the lower parasternal area indicates a post MI ventricular septal defect.

### 307. Bisferians Pulse in Hypertrophic Cardiomyopathy

The type of pulse felt in a Hypertrophic cardiomyopathy is a bisferians pulse (twice peaking pulse) with both peaks in systole. The type of pulse felt in valvular aortic stenosis is Pulsus parvus et tardus.

### 308. Differentiating Austin Flint Murmur of Aortic Regurgitation from a Mid-Diastolic Murmur of Mitral Stenosis

|                             | Austin Flint Murmur of Aortic Regurgitation | Mid-Diastolic Murmur of Mitral Stenosis |
|-----------------------------|---|---|
| 1. Etiology                 | Severe AR (free AR)                         | Rheumatic                               |
| 2. Peripheral Run-off signs | Present                                     | Absent                                  |
| 3. Atrial fibrillation      | -   | Common                                  |
| 4. Pulmonary Hypertension   | -   | Common                                  |
| 5. Apex beat                | Hyperdynamic                                | Tapping                                 |

|                                     | Austin Flint Murmur of Aortic Regurgitation | Mid-Diastolic Murmur of Mitral Stenosis |
|-------------------------------------|---|---|
| 6. S1                               | Normal / Decreased                          | Loud                                    |
| 7. S3                               | Present                                     | Absent                                  |
| 8. Opening Snap                     | Absent                                      | Present                                 |
| 9. Diastolic Thrill                 | Absent                                      | Present                                 |
| 10. Presystolic Accentuation of MDM | Absent                                      | Present                                 |
| 11. Exercise / Amyl Nitrate         | Decreases murmur                            | Increases murmur                        |

### 309. Severity of Mitral Regurgitation

Indicators of Severity of MR are :

- Presence of S3 at the apex that indicates increased flow across the MV due to increased regurgitant volume.
- Functional Mid Diastolic Murmur that indicates increased flow across the MV due to increased regurgitant volume.
- Systolic Thrill at the apex

A soft S1 and a pansystolic murmur can be heard in MR of any severity.

### 310. Murmurs in Aortic Regurgitation

Aortic Regurgitation (AR) produces a *Early Diastolic Murmur* (EDM) at the aortic area or in the left third of fourth parasternal area. The length of the EDM correlates directly with the severity of AR (more severe AR produces longer diastolic murmur). An exception is in acute AR where the murmur may be short in spite of severe AR due to high left ventricular end-diastolic pressure.

Due to the increased regurgitant volume, an *Ejection Systolic Murmur* at the aortic area can be heard radiating to the Carotids (flow murmur). Thus radiation to the carotids is not an indicator of organic aortic stenosis.

Severe 'free' aortic regurgitation can lead to production of a *Mid-Diastolic Murmur* at the apex called the Austin Flint Murmur. It is produced as the regurgitant jet strikes the anterior leaflet of the mitral valve and leads to vibration of the leaflet producing an MDM. Other theories of production of the Austin flint murmur are premature closure of MV due to AR or raised LVEDP in AR producing a diastolic mitral regurgitation producing a MDM.

### 311. Dynamic Auscultation in Hypertrophic Cardiomyopathy

The LVOT gradient in HOCM can be affected by changes in the myocardial contractility, ventricular volume or arterial pressure.

The Gradient *Increases* with

- Increase in Contractility (post VPC, post exercise, during dobutamine infusion)
- Reduction in Ventricular Volume (dehydration, blood loss, valsalva manouver, amyl nitrate infusion).

The Gradient *Decreases* with

- Decrease In Contractility (beta blockers)
- Increase In Ventricular Volume (squatting, isometric hand grip)



The ejection systolic murmur of dynamic LVOT obstruction in Hypertrophic cardiomyopathy varies with various manouvers of dynamic auscultation as follows:

| Increases in Intensity             | Decreases in Intensity          |
|------------------------------------|---------------------------------|
| Valsalva manouever (phase II)      | Isometric hand grip             |
| Standing (from supine position)    | Supine (from standing position) |
| Amyl nitrate                       | Squatting                       |
| During or after Exercise           | Beta blockers                   |
| After a Ventricular premature beat |                                 |

### 312. Named Cardiac Murmurs

|                      |   |                                     |
|----------------------|---|-------------------------------------|
| Austin Flints Murmur | Aortic Regurgitation  | Mid diastolic murmur at apex        |
| Graham Steell Murmur | Pulmonary Regurgitation secondary to Pulmonary hypertension | Early diastolic murmur at Erbs area |
| Carey Coumbs Murmur  | Acute Rheumatic Valvulitis                                  | Mid diastolic murmur at apex        |
| Rogers Murmur        | Ventricular Septal Defect                                   | Pansystolic Murmur                  |
| Gibsons Murmur       | Patent Ductus Arteriosus                                    | Continuous murmur                   |
| Stills Murmur        | Innocent Murmur   | Children                            |
| Rytands Murmur       | Complete Heart Block  | Mid diastolic murmur at apex        |
| Docks Murmur         | Occlusion of Left anterior descending artery                | Diastolic murmur                    |
| Cabot Locke Murmur   | Anemia  | Diastolic murmur                    |

### 313. Continuous Murmurs

Causes:

- A. High to Low Pressure Shunts
  - a. Patent ductus arteriosus
  - b. Aorto pulmonary window
  - c. Post Blalock Taussig Shunt
  - d. Bronchopulmonary Collaterals in Tetralogy of fallot with pulmonary atresia
  - e. Coronary or Peripheral AV Fistulas
  - f. Rupture of sinus of valsalva aneurysm
- B. Arterial Obstruction (Bruit)
  - a. Coarctation of aorta
  - b. Branch Pulmonary Artery stenosis
  - c. Renal, Carotid or Mesentric Artery Stenosis
- C. Increased Flow
  - a. Venous Hum
  - b. Mammary Souffle

### 314. Auscultation in Tetralogy of Fallot

- Single S2 ( only the aortic component)
- Absent P2
- Aortic Vascular Ejection Click (due to dilated aorta)
- Short Ejection systolic murmur (inversely related to the severity of TOF)
- Continuous murmurs of bronchopulmonary collaterals in the axilla, back or chest
- Continuous murmur in patient post – Blalock Taussig Shunt

### 315. Valsalva Manouever

Valsalva manouever involves deep inspiration followed by Forced Expiration against a Closed Glottis. There are four phases – initiation, maintenance, release and overshoot. The findings of dynamic auscultation are described in Phase II or Maintenance phase of Valsalva manouever.

During Phase II there is an increase in the thoracic pressure and a decrease in the venous return to the heart. This leads to a decrease in the stroke volume and blood pressure and a reflex increase in the heart rate.

Effects of Phase II of Valsalva Manouever

Decreased Intensity of all heart sounds and heart murmurs except:

- a. Hypertrophic Cardiomyopathy: Increase in the intensity of the Ejection systolic murmur
- b. Mitral Valve Prolapse: Earlier Click and Longer Systolic murmur

### 316. a: Lowermost and outermost point of maximal impulse in late systole

As isovolumic intraventricular pressure rises, there is anterior and counter clockwise rotation of the LV during **early systole**. This produces an early outward thrust. This is a gentle non sustained tap which lasts for 0.08 seconds. Once the aortic valve opens, blood is ejected during systole. There is medial retraction due to counter clockwise rotation of the LV in late systole.

The apex is located in 4th or 5th intercostal space inside the midclavicular line within 10 cm from midsternal line. It is confined to one intercostal space in a palpable area of 2-2.5 sq cm.

The RV motion is not palpable. Diastolic events are not palpable.

### 317. a: Aortic regurgitation

In normal individuals, RV is neither visible nor palpable. The RV inflow lies behind the left parasternal region of 4th and 5th intercostal space. The infundibular (outflow portion) lies behind the third intercostal space.

Causes of left parasternal pulsations

| Right Ventricular hypertrophy            | Normal Right ventricle                 |
|--|--|
| Pressure overload - PAH, Primary PAH, PS | Moderate to severe MR                  |
| Volume overload - Moderate TR, ASD, VSD  | Regional wall motion abnormality of LV |

318. c: There is increased amplitude and duration of LV ejection

The apex beat is examined in supine position and trunk elevated to 30 degree for localization. The character of apex beat is examined in the left lateral position.

Tapping apex beat - It is characterized by a sharp, short tap due to reduced filling of LV. It is equivalent of loud S1.

Hyperdynamic apex - There is an increase in amplitude and duration of excursion of apical impulse. It gives a partial lift to the examining fingers. It is ill sustained, <50% of systole. It is seen in volume overload states and eccentric LVH.

Heaving apex - There is an increased amplitude and duration of excursion of the apical impulse. This is due to increased duration of LV ejection. There is a sustained lift of the examining fingers which lasts >50% of systole. It is seen in pressure overload conditions and concentric LVH.

Types of Apex beat

| Tapping | Hyperdynamic                      | Heaving  |
|---------|-----------------------------------|--|
| MS      | AR, MR                            | Pressure overload - AS, HCM, systemic hypertension |
|         | PDA, VSD                          | Severe LV dysfunction                              |
|         | AV fistula                        | LV aneurysm  |
|         | Blalock and Waterson shunt        | Severe AR  |
|         | Anemia, Pregnancy, Thyrotoxicosis | Severe ischemic MR                                 |
|         | Thin chest, pectus excavatum      |  |

319. d: Chronic severe mitral regurgitation

| Palpable S3                   | Palpable S4                       |
|-------------------------------|-----------------------------------|
| Left ventricular failure, DCM | AS                                |
| Chronic severe MR             | Hypertrophic Cardiomyopathy (HCM) |
| Children                      | Acute MR, Acute AR                |
| Pregnancy                     | CAD                               |

320. c: Massive pericardial effusion

Rotch's sign - In massive pericardial effusion, the cardio hepatic border becomes obtuse. There may be associated dullness in 2nd ICS also.

321. d: ASD

Causes of clubbing

| Cardiovascular                                    | Pulmonary              | Gastrointestinal   |
|---|------------------------|--------------------|
| Cyanotic CHD - TOF, TGA, TAPVC, Tricuspid Atresia | Bronchiectasis         | Crohn's disease    |
| Infective Endocarditis                            | Emphysema              | Ulcerative colitis |
| Myxoid tumor                                      | Empyema                | Biliary cirrhosis  |
|   | Lung abscess           | Polyposis of colon |
|   | Bronchogenic carcinoma |                    |
|   | Pulmonary tuberculosis |                    |

| Cardiovascular | Pulmonary                    | Gastrointestinal |
|----------------|------------------------------|------------------|
|                | Chronic fibrosing alveolitis |                  |

| Differential clubbing   | Unilateral clubbing            | Unidigital clubbing |
|-------------------------|--------------------------------|---------------------|
| PDA with shunt reversal | Aortic aneurysm                | Hereditary          |
|                         | Brachial arteriovenous fistula | Median n injury     |
|                         | Pancoast tumor                 | Tophaceous gout     |
|                         | Erythromelalgia                | Sarcoidosis         |
|                         | Lymphangitis                   | Trauma              |

322. d: ILD with pulmonary artery hypertension.

Progressively increasing breathlessness with episodes of PND suggests a cardiovascular origin of breathlessness.

323. b: Constrictive pericarditis

Causes of peripheral edema

| Bilateral pitting                              | Unilateral pitting             | Bilateral non pitting | Unilateral non pitting  |
|--|--------------------------------|-----------------------|---|
| CHF  | Trauma                         | Myxedema              | Lymphatic obstruction - filariasis, radiation, trauma, malignancy |
| Constrictive pericarditis                      | Inflammation                   |                       | Milroy's disease  |
| Renal - Glomerulonephritis, Nephrotic syndrome | Baker's cyst                   |                       |   |
| Cirrhosis of liver                             | Varicose veins                 |                       |   |
| Protein losing enteropathy                     | DVT                            |                       |   |
| Nutritional - anemia, hypoproteinemia          | Congenital venous malformation |                       |   |
| Pregnancy, pre menstrual edema                 |                                |                       |   |

324. c: TGA with preductal narrowing, PAH and reverse flow through PDA

Differential cyanosis - Cyanosis of lower limbs with no cyanosis of upper limbs

i. PDA with PAH and reversal of shunt

ii. Coarctation of aorta with interrupted aortic arch with PDA having right to left shunt - Oxygenated blood goes to upper parts of the body and desaturated blood goes to lower part of the body via the PDA

Reverse differential cyanosis - Cyanosis of fingers which exceeds that of toes

- i. TGA with preductal narrowing (coarctation or interrupted aortic arch), PAH and reverse flow through PDA
- ii. DORV with subpulmonary VSD, PAH and reverse flow through PDA
- iii. TGA with intact ventricular septum, PAH and reverse flow through PDA

325. d: Truncus arteriosus

Causes of Cyanosis

| Central cyanosis     | Peripheral cyanosis         | Mixed cyanosis        |
|----------------------|-----------------------------|-----------------------|
| TOF                  | CHF                         | Chronic cor pulmonale |
| Eisenmenger syndrome | Septicemia                  |                       |
| dTGA, TAPVC, DORV    | Cold exposure               |                       |
| Truncus arteriosus   | Peripheral vascular disease |                       |
|                      | Raynaud's phenomenon        |                       |

326. d: Dicrotic notch

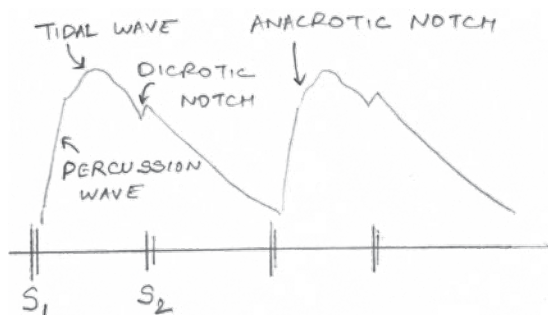


Figure 1

327. a: Hypertrophic obstructive cardiomyopathy

Character and volume of the pulse

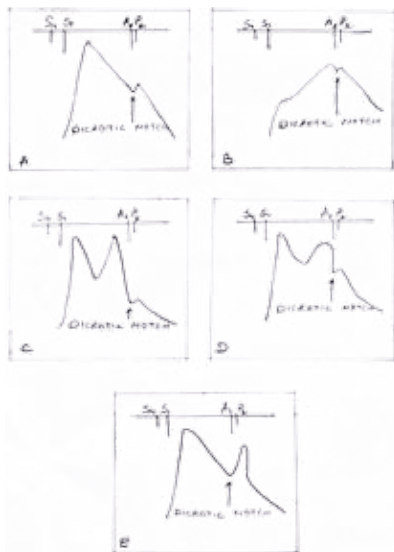


Figure 3

- a. **Hyperkinetic (Bounding) Pulse** - It has larger pulse wave amplitude. It is due to increase in left ventricular ejection, stroke volume, arterial pressure, sympathetic activity or decreased arterial compliance. It is seen in i) elderly subjects with arteriosclerosis and systolic hypertension, ii) anxiety, iii) anemia, iv) thyrotoxicosis, v) exercise, vi) hot and humid environment, vii) alcohol intake and viii) high output states with increased distal arterial runoff like aortic regurgitation, patent ductus arteriosus, large A-V fistula, Paget's disease and severe cirrhosis.
- b. **Hypokinetic Pulse** - A small or diminished pulse is due to low cardiac output with reduced left ventricular stroke volume, shorter left ventricular ejection time or intense vasoconstriction. An unsustained pulse suggests decreased stroke volume without left ventricular outflow obstruction, whereas a slow rising sustained pulse of small volume suggests aortic stenosis. It is seen in i) severe left ventricular dysfunction, ii) congestive cardiac failure, iii) hypotension and iv) left ventricular outflow tract obstruction.
- c. **Pulsus parvus et tardus** - It is a slow rising pulse with delayed systolic peak and upstroke. It is best appreciated with simultaneous auscultation and carotid palpation. In aortic stenosis, it is associated with a carotid thrill (*carotid shudder*).
- d. **Water Hammer (Collapsing pulse) or Corrigan pulse or Pulsus Celer** - This term was coined by *Thomas Watson* after a Victorian toy which comprised of a glass vessel partly filled with water and vacuum. It produces a slapping impact on being turned over. In aortic regurgitation, there is an early, brief peak and a swift descent without dicrotic notch which gives a collapsing sensation. To elicit this, the patient's arm is suddenly raised above the head and the wrist grasped with the examiner's hand so that the palm faces the anterior aspect of wrist. The collapsing nature can be felt after each systole. The brief peak is due to rapid ejection of increased stroke volume. The swift descent is due to diastolic run off (back flow into left ventricle), rapid run off to the periphery due to decreased systemic vascular resistance and reflex vasodilatation mediated by carotid baroreceptors. It may also be seen in hyperkinetic circulatory states like patent ductus arteriosus, aortopulmonary window, arteriovenous fistula, rupture of sinus of valsalva into right heart and tetralogy of Fallot with bronchopulmonary collaterals.
- e. **Double beating pulse** - Simultaneous auscultation and palpation are necessary to delineate the timing of the twice beating pulse.
  - i. **Bisferiens pulse** - The double peaked pulse occurs in systole and is best detected by light but firm compression of the brachial artery with a single finger. It is seen in pure aortic regurgitation, combined aortic stenosis with predominant aortic regurgitation and high output states with normal heart. It is likely to disappear after onset of congestive cardiac failure.
  - ii. **Bifid pulse** - A bifid or spike and dome pattern in systole is recorded, but rarely palpable in significant hypertrophic obstructive cardiomyopathy.
  - iii. **Dicrotic pulse** - The first wave occurs in systole and the second accentuated component is a diastolic reflection wave occurring in diastole. On simultaneous auscultation, S2 separates the two pulse waves. It is better appreciated during inspiration. It is seen in young patients having cardiomyopathy with severe left ventricular dysfunction, low cardiac output, low blood pressure, high systemic vascular resistance, tachycardia, during inspiration in pericardial tamponade, post valve replacement for aortic or mitral regurgitation with left ventricular dysfunction and occasionally with fever in young.

328. b: Dilated cardiomyopathy with severe left ventricular dysfunction

**Pulsus alternans** - It is present during sinus rhythm when patient's peak systolic arterial pressure and pulse volume are alternately strong and weak. It occurs due to beat to beat alteration in left ventricular ejection pressure and signifies severe left ventricular dysfunction. (It is not related to electrical alternans which has a beat to beat variation in the amplitude of QRS complex as seen in massive pericardial effusions). It is best appreciated clinically in the radial or brachial arteries. It may be associated with signs of heart failure like S3 gallop. It can also be detected by slow decompression of the sphygmomanometer cuff while listening to the alteration of Korotkoff sounds. When systolic pressure alternates by >20 mm Hg it can be detected by palpation of the peripheral pulse with patient's breath held in deep expiration. It is accentuated after a PVC, Valsalva maneuver, abrupt upright posture or deep inspiration.

329. b: Pericardial tamponade

**Pulsus paradoxus** - This term was coined by *Kussmaul*. There is marked and exaggerated inspiratory fall in systolic blood pressure in which palpable peripheral arterial pulse and audible Korotkoff sounds disappear in inspiration. The blood pressure cuff is inflated beyond the peak systolic pressure and slowly deflated. The degree of paradoxus is the difference between the systolic pressure at which the Korotkoff sounds are first heard during expiration and the point at which all beats are well heard during both phases of respiration. The word paradoxus is a misnomer because systolic pressure normally falls during inspiration by 4-6 mm Hg. In pulsus paradoxus the difference is >10 mm Hg. The patient must be breathing quietly and not deep breathing or performing Valsalva maneuver. It is seen in pericardial tamponade, constrictive pericarditis, emphysema, asthma, severe congestive cardiac failure and marked obesity.

**Mechanism** - Cardiac tamponade is a continuum from effusion to full blown circulatory collapse. The hemodynamic effects depend on the amount of effusion and the pericardial pressure volume relationship. As fluid accumulates in pericardial sac, there is increased left and right sided atrial and ventricular pressures which equalize at a pressure similar to intrapericardial pressure. Inspiration increases the venous return to the right side of the heart at a period when the total heart volume is fixed. This increases the right ventricular diastolic dimensions pushing the interventricular septum to the left. This reduces left ventricular dimensions, compliance and filling. Also inspiratory pooling of blood into the pulmonary circulation causes under filling of the left atrium and left ventricle. The under filled left ventricle in tamponade operates on the steep ascending limb of Starling curve, so inspiratory reduction of left ventricle filling causes a marked depression of stroke volume and systolic pressure.

Reverse pulsus paradoxus may be seen in cardiac tamponade with positive pressure ventilation and isorhythmic AV dissociation.

Pulsus paradoxus may be absent in cases of cardiac tamponade with atrial septal defect/ ventricular septal defect/ aortic regurgitation/ pericardial adhesions.

330. c: The systolic pressure is estimated by the palpatory method and diastolic pressure by the auscultatory method

**Measurement of blood pressure** - The blood pressure is measured with an aneroid or mercury manometer. The bladder length/width should be 80%/40% of the arm circumference. The ratio of cuff width to length should be 1:2. The center of the rubber bladder should be on the brachial artery. The blood pressure cuff is wrapped tightly around the arm. The diaphragm or bell of the stethoscope is firmly placed at the brachial artery, so that the upper edge of the stethoscope is in contact with the distal edge of the cuff. The patient should be seated comfortably, back supported, bared upper arm, legs uncrossed with the arm at level of heart. The cuff is inflated 20 mm Hg above the point

when the radial pulse is no longer palpable. This palpatory method prevents underestimation of blood pressure due to auscultatory gap. The systolic and diastolic pressures are then estimated by auscultatory method. Cuff should be deflated at <3 mm Hg/sec. The column should be read to the nearest 2 mm Hg. The level of peak systolic pressure is the point at which two consecutive Korotkoff sounds are heard. The disappearance of the Korotkoff sounds is the true diastolic pressure. After every cuff inflation, deflate the cuff completely and allow sufficient time for venous return. There should be no talking between the subject and observer. In severe aortic regurgitation and hyperkinetic circulatory states, the diastolic pressure should be recorded in both phase IV and V. In atrial fibrillation, there is beat to beat variation in blood pressure; hence an average of three readings is taken as a blood pressure. For measurement of lower limb pressure, the patient lies prone; the thigh cuff is wrapped around and auscultate the popliteal fossa. If a thigh cuff is not available, an arm cuff can be wrapped around the lower leg and auscultate the posterior tibial artery or dorsalis pedis artery with a pediatric bell chest piece.

331. b: Mean BP=Diastolic BP + 1/3 pulse pressure

Cardiac output is the product of heart rate and stroke volume ( $CO=HR \times SV$ ). Arterial blood pressure is the product of cardiac output and peripheral resistance ( $BP=CO \times PR$ ). The pulse pressure is the difference between systolic and diastolic blood pressure (approximately 40 mm Hg). Mean blood pressure is the sum of diastolic blood pressure and 1/3rd pulse pressure (approximately 95-100 mm Hg).

332. d: Any position where the peak of the venous column is well identified

The patient should be reclining comfortably without any tension on neck tissues. The chin is elevated and head rotated to the left. It is preferable to have tangential lighting. Lean over to the left side of the patient while examining the right side of the neck. The sternal angle of Louis is 5 cm above the mid right atrium whether supine, 45 degree or 90 degree position is given. The venous pressure is measured from the angle of Louis. The thorax should be positioned at an angle where the peak of the venous column is well identified. If the venous pressure is too low, place the patient supine with leg elevation and ask him to take deep breaths. If the pressure is too high, the pulsations may be behind the angle of the mandible, so keep the patient at 90 degree and examine. The height of the A and V wave during inspiration is taken as the venous pressure. Two scale method is used. A horizontal scale at the peak of the venous column cuts the vertical scale kept at the angle of Louis. For supine 2 cm is the upper limit of normal and for 45 degree 4.5 cm is the upper limit of normal for venous pulsations. By adding 5 cm, we can obtain the actual venous pressure. If it is not visible, deep inspiration can bring out the waves. The normal level is 4 cm above the angle of Louis which is equal to 9 cm of water or 6 mm Hg.

333. c: X descent is between S1 and S2, X' is simultaneous with radial pulse

It is recommended to use the X and Y descent to time the venous pulse. The negative X descent is between S1 and S2 and X' is simultaneous with radial pulse. The A wave is visible as a flickering pulsation just before the carotid pulse is felt. During auscultation, the A wave coincides with S4 and is almost simultaneous with S1. The V wave peaks just after S2 and Y descent begins after the V wave.

334. b: Downward pull of tricuspid valve by contracting RV

Careful examination of the venous pulse can provide useful information about the right sided cardiac physiology (Figure 4). When the right atrium contracts, its pressure rises pushing the blood from right atrium to the right ventricle at end of ventricular diastole. It also causes blood to flow retrogradely into the superior vena cava and jugular veins. This produces a

positive wave called the A wave. The A wave begins at the peak of the P wave of ECG, immediately prior to S1 and the carotid upstroke. As the right atrium starts relaxing, pressure falls causing the early portion of X descent. Simultaneously, the right ventricular systole commences causing the intraventricular pressure to rise above the atrial pressure. This leads to closure of the tricuspid valve. The upward bulging motion of closed tricuspid valve during isovolumic systole produces a positive wave called C wave. The onset of C wave corresponds to the tricuspid component of S1. It can be confused with transmitted carotid pulsations. It is usually not visible as a separate wave. As the right atrial relaxation continues, right atrial pressure falls during early right ventricular systole. During this phase the tricuspid valve ring is also pulled downwards. The latter part of X descent, X' reaches its lowest point. The X descent begins during systole and ends before S2. The great veins empty into the right atrium during ventricular systole with a closed tricuspid valve. This leads to a rise in the right atrial pressure causing a second positive wave called the V wave. It begins in late systole and ends in early diastole. It is synchronous with the carotid pulse and peaks after S2. At this point of early ventricular diastole, the ventricular pressure falls below the intra atrial pressure causing the tricuspid valve to open and blood flows from right atrium to right ventricle. This causes a negative wave called the Y descent. The H (H from *Hirschfelder*) wave arises due to passive right heart filling during diastole. In normal individuals, the A wave is larger than the V wave and X descent is more prominent than the Y descent. During inspiration, negative intrathoracic pressure causes increased venous pooling of blood which leads to prominent X and Y descent. During expiration, A wave diminishes and V wave becomes the dominant positive reflection.

| Wave       | Cause   |
|------------|---|
| A wave     | RA contraction  |
| X descent  | Atrial relaxation   |
| X' descent | RA floor descent and downward pulling of TV by contracting RV |
| C wave     | Impact of carotid artery and upward bulging of TV             |
| V wave     | RA filling during RV systole with a closed TV                 |
| Y descent  | RA emptying when TV opens                                     |
| H wave     | Passive right heart filling during diastole                   |

335. a: Isorhythmic AV dissociation

Abnormalities of the waves

| A waves                          | X descent                  | V waves                   | Y descent                        |
|----------------------------------|----------------------------|---------------------------|----------------------------------|
| <b>Large A waves</b>             | <b>Prominent X descent</b> | <b>Prominent V waves</b>  | <b>Rapid Y descent</b>           |
| TS, RA myxoma, Tricuspid atresia | Constrictive pericarditis  | TR                        | Constrictive pericarditis        |
| PAH, PS, Acute PE                | Cardiac tamponade          | Large ASD                 | Severe TR                        |
| RV cardiomyopathy, RV infarction | ASD                        | Severe CHF, Cor pulmonale | Severe right ventricular failure |
| Severe AS, HCM                   |                            | AF                        | ASD with MR                      |
| <b>Cannon waves</b>              | <b>Absent X descent</b>    | <b>Diminished V waves</b> | <b>Slow Y descent</b>            |

| A waves  | X descent | V waves         | Y descent             |
|--|-----------|-----------------|-----------------------|
| Junctional rhythm, VT, Isorhythmic AV dissociation | TR        | Hypovolemia     | TS, RA myxoma         |
| CHB, Ventricular pacing                            |           | Use of nitrates | Pericardial tamponade |
| <b>Absent A waves</b>                              |           |                 |                       |
| AF, Sinus tachycardia                              |           |                 |                       |

336. a: Pulmonary arterial hypertension

Paroxysmal nocturnal dyspnea - It is occurrence of breathlessness during sleep. Most commonly noticed 2-3 hours after going to sleep and relieved within 15 minutes of sitting upright. It is associated with sweating, wheezing and coughing. These patients are functionally NYHA class III. It is seen in MS, LVF, DCM and CAD

Mechanism of PND

- Absorption of edema fluid from interstitial compartments of lower limbs during supine position increases venous return to right heart. This leads to pulmonary interstitial edema
- Left ventricular failure causes pulmonary interstitial edema and pulmonary venous hypertension.
- Decreased sympathetic drive during sleep decreases LV contractility
- Nocturnal arrhythmias and dreams

337. d: All of the above

Mechanism of syncope in AS

- Due to fixed cardiac output, the cardiac output decreases on exertion due to reflex fall in peripheral vascular resistance
- Exertion causes marked increase in LV contractility with increased LV systolic pressure without corresponding increase in aortic pressure. This leads to stimulation of LV mechanoreceptors causing sympathetic inhibition and parasympathetic activation via the vagal afferent fibres (Bazold Jarisch reflex). This precipitates syncope.
- Myocardial ischemia
- Decreased coronary artery perfusion due to hypotension and bradycardia
- Arrhythmias - AF, Paroxysmal AV block, VT

338. a: Normal pulse pressure

**Acute aortic regurgitation** - In acute aortic regurgitation, there will be sinus tachycardia, slightly low systolic blood pressure with a near normal diastolic blood pressure with pulsus alternans. Peripheral signs may be absent. The mean jugular venous pressure may be elevated.

**Peripheral signs of Chronic Aortic regurgitation**

- Bisferiens pulse - A double peaked systolic impulse, best appreciated in brachial artery
- Water hammer pulse

- iii. Hill's sign - A difference in systolic blood pressure between the brachial and popliteal arteries is used to assess the severity of aortic regurgitation - 20-40 mm Hg - angiographic 2+ AR, 40-60 mm Hg - angiographic 3+ AR, >60 mm Hg - angiographic 4+ AR
- iv. Palmar click - A palpable, abrupt flushing of the palms in systole
- v. Pulsus magnus - High volume, large amplitude pulse

#### Eyes

- v. Landolfi's sign - Contraction and dilatation of pupil in systole and diastole respectively
- vi. Becker's sign - Prominent retinal artery pulsations

#### Head and Neck

- vii. De Musset's sign - Visible oscillation or bobbing of the head with each heart beat
- viii. Corrigan's sign - Visible pulsations of carotid artery (dancing carotids)
- ix. Muller's sign - Visible pulsations of the uvula
- x. Minervi's sign - Strong lingual pulsations demonstrated by up and down movement of the tongue depressor
- xi. Logue's sign - Pulsatile sternoclavicular joint when aortic regurgitation is associated with aortic dissection

#### Upper limb

- xii. Locomotor brachialis - Pulsations of the brachial artery
- xiii. Quincke's pulse - Exaggerated sequential reddening and blanching of the fingernail when light pressure is applied to the tip of fingernail. A similar phenomenon can be observed by pressing a glass slide against the lips.
- xiv. Palfrey's sign - Pistol shot sounds over the radial artery

#### Lower limb

- xv. Pistol shot of Traube - A large systolic sound with the stethoscope lightly placed on the femoral artery
- xvi. Durozeiz's sign - Light pressure applied to the femoral artery distal to the edge of the stethoscope produces a to and fro bruit caused by exaggerated reversal of flow in diastole.

A systolic murmur is perceived by pressing the femoral artery proximal to the stethoscope.

#### Abdomen

- xvii. Rosenbach's sign - Pulsatile liver
- xviii. Gerhardt's sign - Pulsatile spleen
- xix. Dennison's sign - Pulsatile cervix

339. d: Severe TR

**Tricuspid regurgitation - Pulse** - Hemodynamically significant tricuspid regurgitation may result in low amplitude arterial pulse. Many patients may have associated atrial fibrillation.

**Jugular venous pressure** - It has more diagnostic importance than auscultation. Sometimes, in severe tricuspid regurgitation, the mean venous pressure is elevated. In such a situation, it may be necessary to examine the patient in a sitting or standing position. Do not conclude that the jugular venous pulse is normal unless the upper level of the wave form is identified in supine, 45 degree or sitting position. As the severity increases,

X descent is attenuated and ultimately disappears. The V wave is augmented and Y descent is more prominent. In severe tricuspid regurgitation, there is a rounded or plateau like severe regurgitant C-V wave, V wave or S wave. This V wave is a systolic wave which is followed by a sharp, steep trough called the Y descent. In severe cases, prominent eyeballs and pulsatile earlobes have been observed. With inspiration, due to increase in right ventricular inflow, the V wave has a higher peak and a prominent Y descent. In atrial fibrillation, there is disappearance of A wave with presence of a dominant V wave which may simulate the V wave of tricuspid regurgitation.

340. a: Constrictive pericarditis

Explanation - Refer Q 335

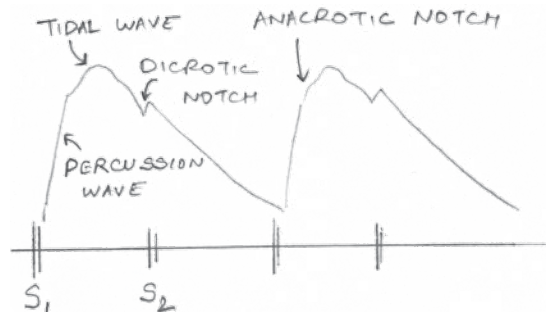


Figure1

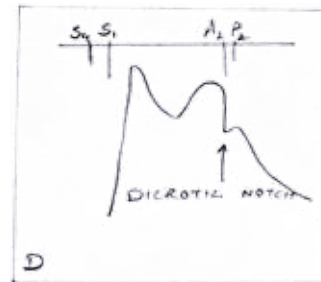


Figure2

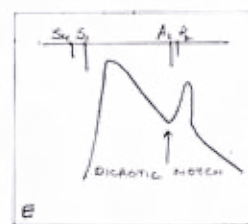
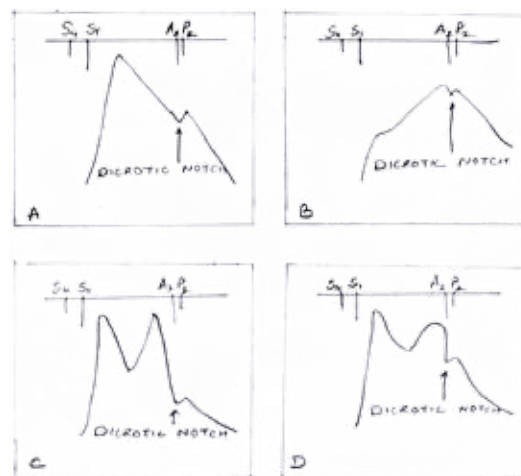


Figure3

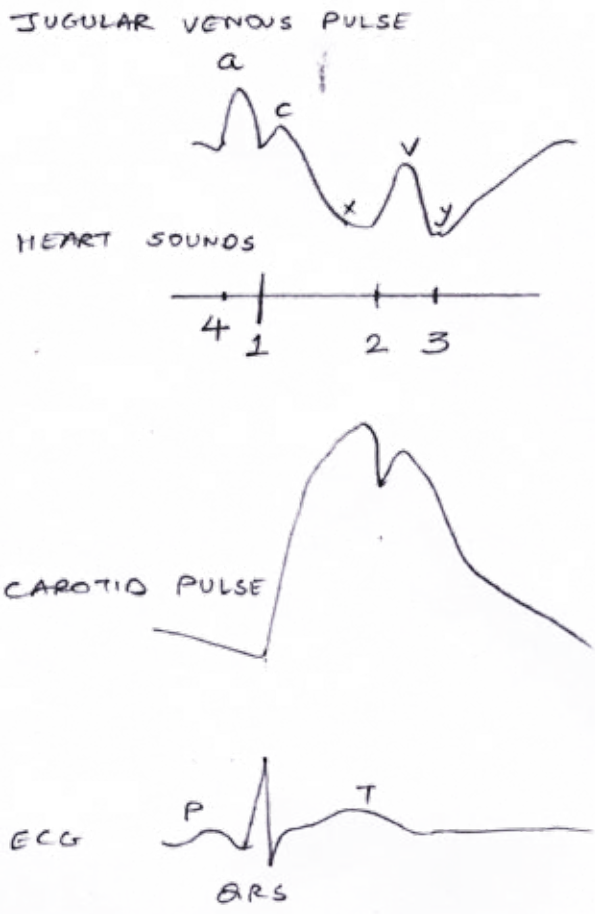


Figure 4

Figure 1: Normal arterial pulse. Note the rapid upstroke of percussion wave, rounded peak of tidal wave and fall off in late systole. The dicrotic notch coincides with S2.

Figure 3: Carotid pulse waveforms and heart sounds. A - Normal, B - Severe Aortic stenosis - anacrotic pulse with slow upstroke, C - Severe aortic regurgitation - bifid pulse with two systolic peaks, D - Hypertrophic obstructive cardiomyopathy - bifid pulse with spike and dome pattern, E - Dicrotic pulse - one peak in systole, another in diastole.

Figure 4: Normal jugular venous pulse. The large A wave almost coincides with S1 and the V wave coincides with S2. The X descent occurs in systole and Y descent in diastole.